




UDC 616.517:616.516.5:615.262.2

<https://doi.org/10.26641/2307-0404.2022.4.271220>

T.V. Svyatenko, 
O.A. Starostina*, 
S.V. Zakharov, 
S.V. Solovyiova

RESULTS OF USING BLUE CAP® FOAM FOR SKIN CARE WITH SIGNS OF XEROSIS

Dnipro State Medical University
V. Vernadskyi str., 9, Dnipro, 49044, Ukraine
Дніпровський державний медичний університет
вул. В. Вернадського, 9, Дніпро, 49044, Україна
*e-mail: starostina.derm@gmail.com

Цитування: Медичні перспективи. 2022. Т. 27, № 4. С. 177-184

Cited: *Medicni perspektivi*. 2022;27(4):177-184

Key words: xerosis, atopic dermatitis, acne, seborrheic dermatitis, rosacea, correction of skin dryness, emollients
Ключові слова: ксероз, атопічний дерматит, акне, себорейний дерматит, розацеа, корекція сухості шкіри, емоменти

Abstract. The results of using Blue cap® foam for skin care with signs of xerosis. Svyatenko T.V., Starostina O.A., Zakharov S.V., Solovyiova S.V. A significant increase in the severity of clinical manifestations of various dermatoses accompanied by dry skin often increases the feeling of discomfort and itching of the skin, significantly reducing the patient's quality of life. This leads to the search for effective ways to correct the dryness of the skin and maintain the proper functioning of the epidermal barrier of the skin in various dermatoses. The aim of the study was to study the effect of using a combined emollient, which includes components of a classic emollient (with the inclusion of ceramides and substances with moisturizing and softening effects), as well as substances with antiseptic and fungistatic effects. The results of treatment of 100 patients with skin diseases and conditions accompanied by dry skin and itching were analyzed. The study group included patients with acne undergoing treatment with retinoids and external preparations with an irritating effect, patients with atopic dermatitis in remission, patients with seborrheic dermatitis, rosacea, follicular hyperkeratosis, and skin xerosis. Using the method of corneometry, the dynamics of changes in skin hydration during the use of a combined moisturizer and changes in the indicators of the dermatological index of the quality of life of patients were studied. The data obtained showed a pronounced increase in skin hydration in terms of corneometry after 2 weeks of using an emollient (by an average of 31.6 units or 160%), and after a month of observation, the changes amounted to 36.7 conv. units, i.e. increased by 185%, which proves the effectiveness of using Blue cap® foam to normalize skin hydration. The level of the dermatological index of quality of life during this period decreased from 9.9±0.2 to 7.2±0.2 points, i.e. by 2.7 points or 27%, what also indicates an improvement in the subjective attitude of patients and promotion quality of life of patients. In the course of the study, a significant improvement in skin hydration when using the combined Blue cap® foam to correct signs of skin xerosis was proven. In the case of dermatoses accompanied by itching associated with dry skin, a marked reduction in itching was noticed, as well as a significant improvement in the quality of life of the patient after a month of using the combined moisturizer.

Реферат. Результати використання піни Блу кап® для догляду за шкірою з ознаками ксерозу. Святенко Т.В., Старостіна О.О., Захаров С.В., Соловійова С.В. Істотне збільшення тяжкості клінічних проявів різних дерматозів, що супроводжуються сухістю шкірних покривів, нерідко посилює почуття дискомфорту та свербіжу шкіри, значно знижуючи якість життя пацієнта. Це зумовлює пошук ефективних способів корекції сухості шкірних покривів та підтримання правильного функціонування епідермального бар'єру шкіри за різних дерматозів. Метою дослідження було вивчення ефекту використання комбінованого пом'якшувального засобу, до складу якого входять компоненти класичного емоменту (з включенням до складу керамідів та речовин зі зволожуючою та пом'якшувальною дією), а також введені речовини з антисептичною та фунгістатичною дією. Проаналізовано результати лікування 100 пацієнтів із захворюваннями шкіри та станамі, що супроводжуються сухістю шкіри та свербінням. До групи дослідження увійшли пацієнти з акне на фоні лікування ретиноїдами та зовнішніми препаратами з подразнюючою дією, пацієнти з атопічним дерматитом у стадії ремісії, хворі на себорейний дерматит, розацеа, фолікулярний гіперкератоз та ксероз шкіри. За допомогою методу корнеометрії було досліджено динаміку зміни зволоженості шкіри на фоні застосування комбінованого зволожуючого засобу та зміну показників дерматологічного індексу якості життя пацієнтів. Отримані дані показали виражене збільшення зволоженості шкіри за показниками корнеометрії вже після 2-тижневого застосування пом'якшувального засобу (в середньому на 31,6 од., або на 160%), а через місяць спостереження зміни становили 36,7 ум. од., тобто збільшились на 185%, що доводить ефективність використання піни Блу кап® для нормалізації зволоженості шкіри. Рівень дерматологічного індексу якості

життя в цей період знизився з $9,9 \pm 0,2$ до $7,2 \pm 0,2$ бала, тобто на 2,7 бала, або на 27%, що також свідчить про поліпшення суб'єктивного ставлення пацієнтів та підвищення якості життя пацієнтів. У ході дослідження було доведено значне покращення зволоженості шкіри при застосуванні комбінованого засобу Blue cap® для корекції ознак ксерозу шкіри. У разі дерматозів, що супроводжуються свербінням, пов'язаним із сухістю шкірних покривів, відмічено виражене зниження свербіжесу, а також значне поліпшення якості життя пацієнта після місяця використання комбінованого зволожуючого засобу.

A significant increase in the severity of clinical manifestations of various dermatosis, accompanied by dryness of the epidermis, often increases the feeling of discomfort and itching of the skin, significantly reducing the quality of life of the patient [1]. Scientists believe that one of the main reasons for the development of xerosis is a violation of the structure of the hydrolipid mantle of the skin and the stratum corneum of the epidermis, which leads to increased trans-epidermal water loss, a change in the acidity of the stratum corneum of the epidermis, and can contribute to a decrease in the barrier function of the skin and the activation of opportunistic flora [2, 3]. These changes can further exacerbate the irritating effect of dermatosis and maintain it [4]. It becomes relevant to search for effective ways to correct and maintain the barrier function of the skin in various dermatoses [5, 6]. This approach to the treatment of dermatosis can not only improve the appearance of the skin, but also improves the results of therapy for various various dermatological diseases and maintains stable remission [7].

Not the last role in the treatment and maintenance of stable remission in chronic dermatoses is assigned to the correct selection of cosmeceuticals, which, as a rule, perform the role of moisturizing and soothing agents and, in addition to indifferent components, also contain substances that can provide a moisturizing and protective function.

One of the external means with such characteristics is Blue cap® foam (CATALYSIS, S.L.). It is a multi-component cosmeceutical with moisturizing and protective properties, intended for skin care in chronic dermatoses accompanied by dryness of the skin. The moisturizing foam in question is a new product manufactured by CATALYSIS, S.L. (Spain) and is included in the Blue cap® line of protective products, which also includes cream, shampoo, shower gel and spray.

Blue cap® foam includes active ingredients that are classic components of emollients: glycerin, cholesterol and ceramides NP, AP, EOP, which restore barrier properties, water balance and mechanical strength of the epidermis, reduce the risk of skin infection and prevent transepidermal water loss [15].

The composition also includes such active ingredients as:

1. Bisobolol, which reduces the level of inflammatory mediators in the skin, eliminating the process

of irritation, reducing redness and stimulating healing, reduces peeling in case of excessive dryness and xerosis. These ingredients work synergistically to soothe the skin and restore the skin's hydrolipidic mantle, eliminating skin tightness, flaking and itching.

2. Phytosphingosine exhibits bacteriostatic activity against Staphylococcus aureus, Streptococcus pyogenes, Micrococcus luteus, Propionibacterium acnes, Brevibacterium epidermidis.

3. Activated pirocton olamine has a bacteriostatic effect and a pronounced fungistatic effect in relation to Pityrosporum ovale and Candida albicans.

The inclusion of the last three active ingredients in Blue cap® foam is based on the opinion of a number of authors, who attribute one of the key roles in the development and course of chronic dermatoses to the activation of opportunistic flora on the surface of the skin, such as Pityrosporum ovale, Candida albicans, Candida albicans epididmidis.

The activity of this microflora can significantly increase and prolong the course of chronic dermatoses in patients. This feature is associated with the release of inflammatory mediators in the places where these microorganisms multiply and penetrate into the skin and the concomitant increase in desquamation of the horny scales of the epidermis. This leads to increased permeability of the skin's hydrolipidic mantle, increased transepidermal water loss, and further increased skin dryness, irritation and inflammation. [17, 18].

The purpose of the study was an evaluation of the effectiveness of the use of a combined emollient – Blue cap® foam to increase skin hydration in patients with skin diseases accompanied by dryness and discomfort.

MATERIALS AND METHODS OF RESEARCH

We observed 100 people aged 18 to 72 years (mean age 34.2 ± 1.5 years), including 45 men and 55 women.

The research was approved by the Biomedical Ethics Commission of Dnipro State Medical University and was conducted in accordance with the principles of bioethics set out in the WMA Declaration of Helsinki – “Ethical principles for medical research involving human subjects” and “Universal Declaration on Bioethics and Human Rights” (UNESCO). All patients signed an informed consent to participate in the study.

A detailed survey of patients revealed that all study participants to some extent experienced

discomfort associated with dryness, tightness, burning and itching of the skin, which worsened the course of the underlying disease and reduced the quality of life of the patient.

Of these, 20 people (20%) had acquired dry skin on the background of acne treatment with systemic retinoids, 15 people (15%) experienced facial skin discomfort due to treatment with topical antibacterial drugs and azelaic acid (7 people were treated for rosacea and 8 people received topical treatment for mild acne). The study group also included patients diagnosed with seborrheic dermatitis (13 patients), chronic course. Patients with this nosology had severe discomfort in the face and back: peeling, moderate redness of the skin, which persisted for a long time despite external therapy.

All patients on the background of ongoing therapy were recommended to use Blue cap[®] moisturizing foam for 4 weeks, which includes ceramides, natural moisturizing factor components, bisabolol and piroctone olamine [19].

13 patients used Blue cap[®] foam as a moisturizing agent for the care of atopic skin in remission, manifestations of lichenification and peeling in typical places. As a moisturizer, Blue cap[®] was used in 32 patients with severe xerosis of the skin of various nature (both hereditary and acquired). This group included patients with persistent dry skin after COVID-19 infection (4 patients) and other viral infections, xerosis that developed as a result of chronic endocrine pathologies, older patients with senile itching against the background of prolonged severe dry skin, as well as 8 patients who according to various indications, oral contraceptive pills (OCPs) were used for a long time and dryness and moderate itching of the skin of the face and chest were noted. In 7 patients, against the background of dryness, follicular hyperkeratosis was noted.

The distribution of patients from different groups included in the study by gender and age is presented in Table 1.

Table 1

Distribution of patients with dry skin symptom complex by gender and age

Observation group	Number of observations (n)	Gender: male/female	Age, years		
			minimum-maximum	M±m	significant differences with group*
Dryness of the skin in seborrheic dermatitis	thirteen	11/2	26-44	35.5±1.7	p - 1, 2, 4, 6, 8
Dryness of the skin in acne on the background of treatment with systemic retinoids	20	11/9	18-29	23.4±0.7	p - 3, 5, 7, 8
Dryness of the skin against the background of external treatment of acne	8	3/5	18-28	23.1±1.1	p - 3, 5, 7, 8
Dryness of the skin against the background of external treatment of rosacea	7	0/7	28-39	34.0±1.4	p - 1, 2, 4, 6, 8
Dryness of the skin in atopic dermatitis	thirteen	6/7	18-35	23.2±1.3	p - 3, 5, 7, 8
Dryness of the skin in follicular hyperkeratosis	7	2/5	18-26	22.6±1.3	p - 3, 5, 7, 8
Dryness of the skin on the background of OCPs use	8	0/8	28-36	32.3±1.0	p - 1, 2, 4, 6, 8
Dryness of the skin of other etiology	24	12/12	35-72	56.3±2.1	p - 1, 2, 3, 4, 5, 6, 7
All patients	100	45/55	18-72	34.2±1.5	

Notes: * – number of groups with significant differences in average age indicators ($p < 0.05$); in all cases, differences between the means in relation to the initial data are significant at $p < 0.001$ (according to the Wilcoxon test).

The diagnosis of diseases was established at the initial visit based on the anamnesis, clinical picture, physical examination and analysis of laboratory parameters.

Skin hydration was determined by a hydration test (corneometry), which allows assessing the hydration of the stratum corneum of the epidermis, using a Soft Plus device (Callegary, Italy). The test is based on

determining the capacitive properties of the skin – the change in the dielectric properties of the skin depending on the amount of hydration contained in the stratum corneum. The diameter of the measuring head of the sensor is 1 cm, the measurement time is 1 second. The hydration content of the skin of three zones was determined: cheek, back, forearm.

Corneometry – determination of the amount of hydration in the stratum corneum, usually used to evaluate the moisturizing effect of emollients. From our point of view, corneometry, being a fairly simple technique, allows you to quickly and effectively determine the skin's response to moisturizing [14].

The research was carried out in the autumn-winter period, in a room with central heating, with an air temperature of about 23°C and air humidity in the room no more than 24%. The study was conducted on clean skin that had not been treated with external products for 8 hours and had not been in contact with water for 2 hours before the study.

In patients with acne, rosacea and seborrheic dermatitis (whose rash was localized on the face), corneometry was performed at two points – in the area of the cheek and forehead.

In other patients, in whom dryness of all skin layers was noted, corneometry was performed on the skin at three points: in the area of the cheek, shoulder, and abdomen, and the average indicator of the patient's corneometry was determined.

The result of corneometry was evaluated in conv. units and compared with the rating scale:

- up to 15 conv. units – pronounced dryness of the skin;
- 16-45 conv. units – moderate dryness of the skin;
- 46-65 conv. units – normal skin hydration;
- 66 conv. units and above – good skin hydration.

The study was carried out in the autumn-winter period, in a room with central heating, with an air temperature of about 23°C and air humidity in the room no more than 24% [10].

To assess the subjective sensations of patients and changes in the level of quality of life in dermatological pathologies, a specially developed questionnaire Dermatology Life Quality Index – DLQI, consisting of 10 points and including estimated indicators from 0 to 3 points with a maximum sum of 30 points (the patient's quality of life is inversely proportional to the sum of the points). The results were evaluated according to the following criteria: a result from 1 to 10 points corresponded to a mild degree of a decrease in the quality of life, a result from 11 to 20 points corresponded to a moderate degree of a decrease in the quality of life, and a result from 21 to 30 points corresponded to a severe degree [12].

The dynamics of the process was monitored using corneometry on the 14th and 30th day of observation, the change in the DLQI – on the 30th day of observation.

Statistical processing of the study materials was carried out using the Statistica v6.1 software package (Statsoft Inc. USA, serial no. AGAR909E415822FA). The mean values of the indicators are presented as the arithmetic mean (M), its standard error (m), and 95% confidence interval (95% CI).

Considering the small size of the study samples, when comparing averages over time, the nonparametric Wilcoxon test was used for dependent samples, and for independent samples – the Duncan test. When comparing relative values, Pearson's fit test (Pearson Chi-square – χ^2) was used. The relationship between traits was assessed by Spearman's rank correlation coefficients (Spearman – r). Critical level of statistical significance (p) when testing statistical hypotheses [13].

RESULTS AND DISCUSSION

At the initial measurement of skin hydration, the indicators in patients of all studied groups corresponded to severe (42%) and moderate (58%) skin dryness, varying from 9 to 40 conventional units. units and averaging 19.8 ± 0.8 conv. units

The most pronounced manifestations of dry skin (corneometry score – up to 15 conv. units) were observed in patients with atopic dermatitis (77% of patients), with skin xerosis of various etiologies (54%) and while taking OCPs (63%), as well as in patients undergoing acne treatment with systemic retinoids (45%) (Fig. 1). At the same time, no significant correlation was found between the initial indicators of skin hydration and gender ($r=0.02$, $p>0.05$) and age ($r=0.09$, $p>0.05$) characteristics of patients.

The results of conducted clinical study showed the high efficiency of Blue cap® foam after 2 weeks of its use in all groups of patients (Table 2).

In patients with acne on the background of taking retinoids and external therapy, the index of facial skin hydration significantly ($p<0.001$) increased by 35.9 conv. units (by 198%) and 33.1 conv. units (by 121%), respectively, in 2 weeks with a further improvement in performance by the next visit. An increase in the indicator by more than 2 times ($p<0.001$) was noted in seborrheic dermatitis and against the background of external treatment of rosacea. In the first case, the degree of skin hydration increased by 29.7 conventional units. units (by 113%) in 14 days from the start of the Blue cap® foam application and by 34.6 conv. units (by 132%) by the end of the observation month. In rosacea against the background of external treatment, the hydration index in the corresponding periods of observation increased by 29.6 conv. units (by 108%) and by 32.2 conv. units (by 118%) from the initial level.

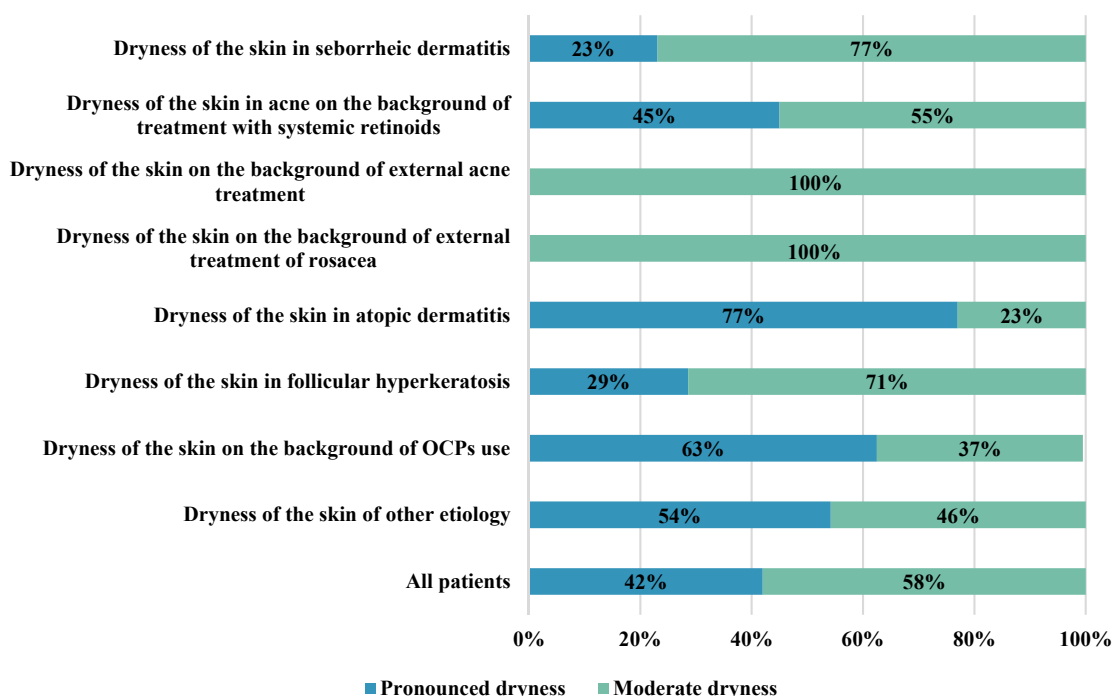


Fig. 1. Distribution of corneometry indicators by the level of skin hydration in patients with symptom complex of dry skin before the use of Blue cap® foam

In atopic dermatitis, follicular hyperkeratosis, skin xerosis of various etiologies and against the background of taking OCPs, despite a significantly reduced initial hydration content of the skin of the trunk and extremities (mean values varied (95% CI) from 9.3 to 22.4 c.u.) , after a month of application, the indicators increased by more than 30 conventional units. units (3 or more times)

at $p < 0.001$. According to the results of corneometry, the average indicators of skin hydration amounted to 50.2 ± 2.1 conv. units in patients with atopic dermatitis, 53.1 ± 2.7 conv. units – with follicular hyperkeratosis, 56.3 ± 2.0 conv. units and 47.5 ± 3.5 conv. units – with xerosis of the skin of various etiologies and against the background of taking OCPs (Table 2).

Table 2

Dynamics of changes in skin hydration indicators in patients with dry skin symptom

Observation groups	At the beginning of treatment	In 2 weeks		In 30 days	
	M±m, mind. unit	M±m, mind. unit	Δ (%)	M±m, mind. unit	Δ (%)
Dryness of the skin in seborrheic dermatitis	26.3±2.3	56.0±2.7	29.7 (113%)	60.9±2.2	34.6 (132%)
Dryness of the skin in acne on the background of treatment with systemic retinoids	18.1±1.5	54.0±1.7	35.9 (198%)	58.9±1.6	40.8 (225%)
Dryness of the skin on the background of external acne treatment	27.3±2.2	60.4±4.3	33.1 (121%)	64.0±4.3	36.7 (134%)
Dryness of the skin on the background of external treatment of rosacea	27.4±1.2	57.0±4.2	29.6 (108%)	59.6±4.6	32.2 (118%)
Dryness of the skin in atopic dermatitis	15.8±1.9	46.2±2.4	30.4 (192%)	50.2±2.1	34.4 (218%)
Dryness of the skin in follicular hyperkeratosis	15.7±1.6	44.4±2.9	28.7 (183%)	53.1±2.7	37.4 (238%)
Dryness of the skin on the background of OCPs use	15.9±2.8	40.3±3.5	24.4 (153%)	47.5±3.5	31.6 (199%)
Dryness of the skin of other etiology	17.8±1.3	50.9±1.8	33.1 (186%)	56.3±2.0	38.5 (216%)
All patients	19.8±0.8	51.4±1.0	31.6 (160%)	56.5±1.0	36.7 (185%)

Notes: Δ (%) – change in the indicator in relation to the initial data in conv. units (in %); in all cases, the differences between the means in relation to the initial data are significant at $p < 0.001$ (according to the Wilcoxon test).

In general, the use of the emollient Blue cap® for a month in patients of all groups with skin diseases accompanied by dryness (n=100) made it possible to improve skin hydration by an average of 36.7 conventional units. units (by 185%) compared to the original level. As a result, 60% of patients had normal corneometry, 29% had well-moisturized skin, and only 11% of patients had moderate dry skin (Fig. 2).

Moderate results were predominantly observed in older patients with skin xerosis of various etiology (n=3-13%) and on the background of OCPs treatment (n=3-37%), with atopic dermatitis (n=2-15%), follicular hyperkeratosis, as well as against the background of external treatment of rosacea and acne (1 case each).

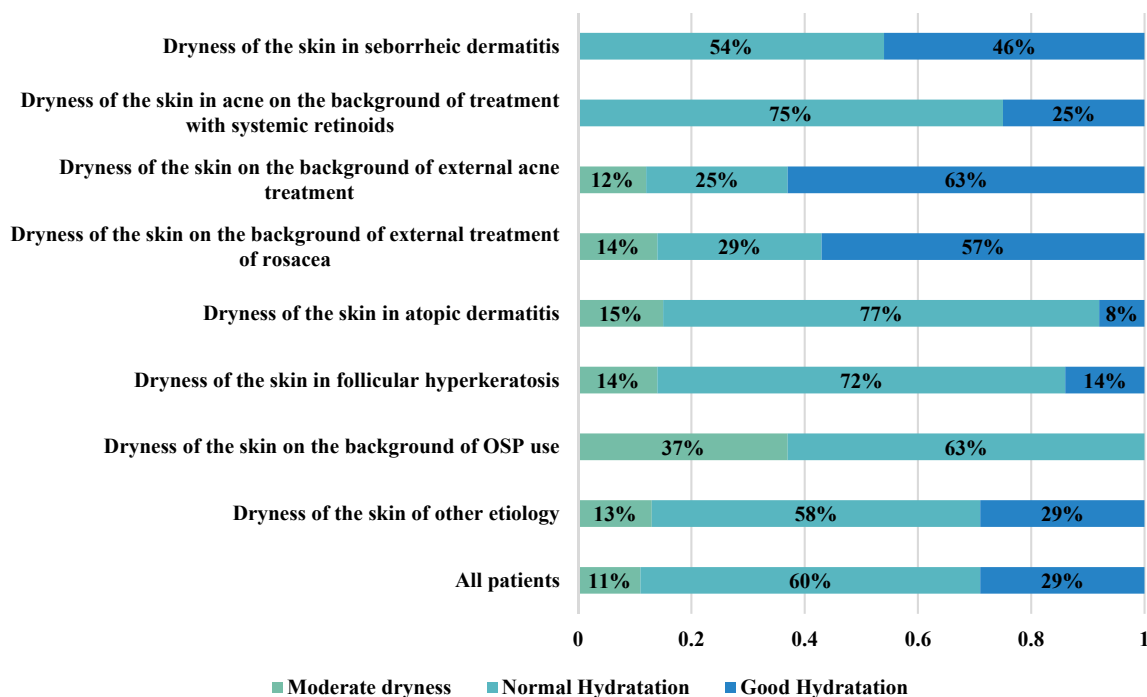


Fig. 2. Distribution of corneometry indicators by the level of skin hydration in patients with symptom complex of dry skin in 30 days of using Blue cap® foam

During the initial assessment of the subjective sensations of patients and changes in the quality of life in dermatological pathologies using the DLQI questionnaire, the quality of life (discomfort) of moderate severity (11-20 points on the DLQI scale) was noted in 27% of patients, mainly in patients suffering from atopic dermatitis (38%), acne (32%), rosacea (43%) and seborrheic dermatitis (31%), as well as xerosis of the skin of various etiologies (21%). At the same time, only in the last group of patients, the quality of life indicator before treatment directly correlated with the age of patients ($r=0.47$, $p<0.05$). The total score of DLQI in patients of all studied groups varied from 7 to 20 points and averaged 9.9 ± 0.2 points.

After 4 weeks of using the Blue cap® foam, the level of the dermatological index of quality of life decreased to 7.2 ± 0.2 points, i.e. by 2.7 points or 27% ($p<0.001$). Positive dynamics of changes in the index of DLQI was noted in all selected groups of patients – the decrease in the average index varied from 17% ($p<0.01$) in seborrheic dermatitis to 34% ($p<0.001$) in

patients with dry skin on the background of topical acne treatment (Table 3).

Only in 5 patients included in the study, the level of DLQI after the use of an emollient met the criteria for moderate severity, i.e. the percentage of such patients decreased from 27% to 5% ($p<0.001$).

Thus, the data obtained showed a pronounced increase in skin hydration in terms of corneometry after 2 weeks of using an emollient (by an average of 31.6 units or 160%), and after a month of observation, the changes amounted to 36.7 units, i.e. increased by 185%, which proves the effectiveness of using Blue cap® foam to normalize skin hydration. The level of the dermatological index of quality of life during this period decreased from 9.9 ± 0.2 to 7.2 ± 0.2 points, i.e. by 2.7 points or 27%, which also indicates an improvement in the subjective attitude of patients and an increase in the quality of life of patients.

The data obtained during this study are confirmed by data of other studies that indicate the effectiveness of Blue cap® foam.

Table 3

**Dynamics of changes in the level of DLQI when using an emollient
in patients with dry skin symptom**

Observation groups	At the beginning of treatment	In 30 days	
	M±m, score *	M±m, score *	Δ (%)
Dryness of the skin in seborrheic dermatitis	10.5±0.9	8.7±0.9 # (p - 4,7,8)	-1.8 (-17%)
Dryness of the skin in acne on the background of treatment with systemic retinoids	10.1±0.4	7.2±0.3 ##	-2.9 (-29%)
Dryness of the skin on the background of external acne treatment	9.8±0.6	6.5±0.5 ## (p - 5)	-3.3 (-34%)
Dryness of the skin on the background of external treatment of rosacea	10.1±0.7	7.6±0.8 #	-2.5 (-25%)
Dryness of the skin in atopic dermatitis	10.8±0.9 (p - 7)	7.5±0.9 ##	-3.3 (-31%)
Dryness of the skin in follicular hyperkeratosis	9.0±0.6	7.1±0.7 #	-1.9 (-21%)
Dryness of the skin on the background of OCPs use	8.4±0.4 (p - 1)	6.3±0.4 # (p - 5)	-2.1 (-25%)
Dryness of the skin of other etiology	9.6±0.4	6.7±0.2 ## (p - 5)	-2.9 (-30%)
All patients	9.9±0.2	7.2±0.2 ##	-2.7 (-27%)

Notes: * – in brackets are the numbers of groups with which there are significant differences in the average values of DLQI ($p < 0.05$); in all cases, the differences between the averages in relation to the initial data are significant at # – $p < 0.01$; ## – $p < 0.001$ (Wilcoxon test); Δ (%) – change in the indicator in relation to the initial data in points (in %).

Thus, according to the study conducted in Slovakia in 2022, which analyzed the effectiveness of the moisturizing effect of Blue cap[®] foam in patients with psoriasis and seborrheic dermatitis, a significant reduction in peeling and dryness of the skin and a decrease in the manifestations of dermatoses during the use of the product have been noted [16].

Clinical improvement in the course of psoriasis, seborrheic dermatitis and atopic dermatitis is also evidenced by the data of studies in Kazakhstan, which noted an improvement in the dermatology quality life index during the two-week use of Blue cap[®] foam. At the same time, the overall decrease in the DLQI index was 58% in psoriasis, 70.1% in seborrheic dermatitis, and 73.9% in atopic dermatitis [20].

So, the data obtained in the course of the considered studies testify to the validity of prescribing Blue cap[®] foam to patients with dermatitis accompanied by skin dryness.

CONCLUSIONS

1. Daily use of Blue cap[®] foam in patients suffering from skin diseases accompanied by dryness and discomfort leads to the restoration of skin hydration to a high level.

2. Among the patients who used the Blue cap[®] foam, there was a good tolerance of the foam, easy absorption, rapid elimination of visible dryness of the skin and improvement in subjective sensations. Adverse reactions to the Blue cap[®] foam during therapy were not observed.

Contributors:

Svyatenko T.V. – conceptualization, resources;
Starostina O.A. – methodology, research;
Zakharov S.V. – curation of data, formal analysis;
Solovyiova S.V. – methodology, research.

Funding. This research received no external funding.

Conflict of interests. The authors declare no conflict of interest.

REFERENCES

1. Vyumvuhore RR, Michael-Jubeli R, Verzeaux L, Boudier D, Le Guillou M, Bordes S, et al. Lipid organization in xerosis: the key of the problem? *Int J Cosmet Sci*. 2018;40(6):549-54. doi: <https://doi.org/10.1111/ics.12496>
2. Kovalova TM, Polovko NP. [Xerosis: Causes and Review of the Progressive Correction]. Collection of scientific works of NMAPE named after PL Shupyk. 2015;24(2):405-09. Ukrainian.
3. Kaliuzhnaia LD. [Modern external therapy for dry aging skin]. *Ukr. J. dermatol., venerol., kosmetol.* 2005;18(3):33-35. Ukrainian.

4. Sviatenko TV, Kharitonova OG, Starostina OA. [Complex therapy and rehabilitation of patients with rosacea]. *Dermatolohiia ta venerolohiia*. 2014;(4):93-99. Ukrainian.
5. Sviatenko TV, Starostina OA. [Analysis of the antipruritic effect of the combined use of desloratadine and dimethindemate in the treatment of allergic dermatosis in children]. *Health of Ukraine*. 2021;16(4):46-52. Ukrainian.
6. Arora D, Garg S. Skin Care of Acne Vulgaris in Sensitive Skin. *The Sensitive Skin: Treatment Modalities and Cosmeceuticals*. 2019:3.
7. Guanti MB, Bonzano L, Rivi M, Alicandro T, Liberati S, Hebert AA, et al. Efficacy and Safety of an Antioxidant-Enriched Medical Device for Topical Use in Adults with Eczematous Dermatitis. *Dermatology and Therapy*. 2022;12(4):1015-25. doi: <https://doi.org/10.1371/journal.pone.0231078>
8. Huang Y-x, Li J, Zhao Z-x, Zheng B-l, Deng Y-x, Shi W, et al. Effects of skin care habits on the development of rosacea: a multi-center retrospective case-control survey in Chinese population. *PLoS ONE*. 2020;15(4):e0231078. doi: <https://doi.org/10.1371/journal.pone.0231078>
9. Stettler H, Crowther JM, Brandt M, Lu B, Boxshall A, de Salvo R, et al. Targeted dry skin treatment using a multifunctional topical moisturizer. *International Journal of Cosmetic Science*. 2021;43(2):191-200. doi: <https://doi.org/10.1111/ics.12680>
10. Yosipovitch G, Misery L, Proksch E, Metz M, Ständer S, Schmelz M. "Skin Barrier Damage and Itch: Review of Mechanisms, Topical Management and Future Directions." *Acta Derm Venereol* 2019;99:1201-9. doi: <https://doi.org/10.2340/00015555-3296>
11. Sutton E, Shaw AR, Ridd MJ, Santer M, Roberts A, Baxter H, et al. How parents and children evaluate emollients for childhood eczema: a qualitative study. *British Journal of General Practice*. 2022;72(719):e390-e7. doi: <https://doi.org/10.3399/BJGP.2021.0630>
12. Koliadenko VG, Chernyshov PV. [Indicators of the quality of life in dermatological ailments]. *Ukr. J. dermatol., venerol., kosmetol.* 2005;2:11-14. Ukrainian.
13. Peacock J. Peacock P. *Oxford Handbook of Medical Statistics*. Oxford medical handbook; 2010. doi: <https://doi.org/10.1093/med/9780199551286.001.0001>
14. Cekiera A, Popiel Ja, Siemieniuch M, Jaworski Z, Slowikowska M, Siwinska N, et al. The examination of biophysical parameters of the skin in Polish Konik horses. *PLoS ONE*. 2021;16(6):e0250329. doi: <https://doi.org/10.1371/journal.pone.0250329>
15. Moore DJ, Rawlings AV. The chemistry, function and (patho) physiology of stratum corneum barrier ceramides. *International journal of cosmetic science*. 2017;39(4):366-72. doi: <https://doi.org/10.1111/ics.12399>
16. Zelenkova H, Pavlickova D. Effectiveness of activated piroctone olamine in the treatment of psoriasis and seborrheic dermatitis. *Dermatology DOST Svidnik*. 2022;1:43.
17. Baurecht H, et al. Epidermal lipid composition, barrier integrity, and eczematous inflammation are associated with skin microbiome configuration. *Journal of Allergy and Clinical Immunology*. 2018;141(5):1668-76.e16 doi: <https://doi.org/10.1016/j.jaci.2018.01.019>
18. Lefèvre-Utile A, Braun C, Haftek M, Aubin F. Five functional aspects of the epidermal barrier. *International Journal of Molecular Sciences*. 2021;22(21):11676. doi: <https://doi.org/10.3390/ijms222111676>
19. [Expert conclusion No. K-486]. Kyiv: Chamber of Commerce and Industry [Internet]. 2021 April 27. Ukrainian. Available from: <https://kiev-chamber.org.ua/>
20. Batpenova GR, Tsoi NO. [The results of a clinical study and assessment of the effectiveness of the casting of Blue Cap® Foam]. *Theses of Astana cal University*. 2022:4-6. Ukrainian.

Стаття надійшла до редакції
07.06.2022

