

**Hamid Dahmarde,
Faramarz Fazeli ***

**SHOULD RENAL RESISTIVE INDEX BE CONSIDERED
AS A ROUTINE PREDICTOR IN NEWLY DIAGNOSED
ACUTE HYDRONEPHROSIS IN PATIENTS
WITH UNILATERAL RENAL COLIC?**

Zahedan University of Medical Sciences
Zahedan, Sistan and Baluchestan, Iran
Університет медичних наук, Захедан
Захедан, Сістані Белуджистан, Іран
*e-mail: 30stana@gmail.com

Цитування: Медичні перспективи. 2022. Т. 27, № 3. С. 72-78

Cited: Medicni perspektivi. 2022;27(3):72-78

Key words: renal resistive index, renal colic, acute hydronephrosis

Ключові слова: нирковий резистивний індекс, ниркова коліка, гострий гідронефроз

Abstract. Should renal resistive index be considered as a routine predictor in newly diagnosed acute hydronephrosis in patients with unilateral renal colic? Hamid Dahmarde, Faramarz Fazeli. Urinary tract stones are the most common causes of urinary tract obstruction, leading to patient hospitalization in the emergency room. This study is aimed to evaluate the use of the mean resistance index (mRI) to predict hydronephrosis in patients admitted for acute renal colic. This prospective study was performed on 100 patients who were admitted to the emergency department (ED) with unilateral renal colic (RC) problem. At the first visit, the following was done for all patients: 1. blood was taken from them for laboratory studies; 2. ECG and cardiological test; 3. plain film of the urinary tract; 4. abdominal US; 5. bilateral color doppler ultrasound (CDUS) with renal RI measurement. Based on the information collected at different times during the experiment, patients were divided into two groups: the group that showed signs of dilatation (group A) and the group with hydronephrosis (group B). The obtained data were analyzed statistically by SPSS version 20. A mRI with a 0.68 cut off value was the most accurate (AUC:0.878), and Sensitive (90%) cut-off value for prediction of hydronephrosis development among patients presenting with RC and renal stone. This cut-off value also provided the highest positive (94%) and negative (76%) predictive values. CDUS with RI measurement is an easy and non-invasive method that provides useful information about urinary tract obstruction stones in patients with unilateral RC. In our study, this method was able to predict successfully the onset of acute renal dilatation. This was done with different levels of sensitivity, specificity, accuracy and diagnostic efficiency that were higher than ultrasound. Daily use of CDUS in ED can improve ultrasound, especially when other methods are contraindicated. For example, the methods by which the patient is exposed to radiation (pregnancy, allergies, renal failure, etc.) or intravenous injection of contrast agents (urography and CT).

Реферат. Чи слід розглядати нирковий резистивний індекс як рутинний предиктор при вперше діагностованому гострому гідронефрозі в пацієнтів з односторонньою нирковою колікою? Гамід Дахмарде, Фарамарз Фазелі. Каміні в сечовивідних шляхах є найпоширенішою причиною обструкції сечовивідних шляхів, що призводить до госпіталізації пацієнтів у відділення невідкладної допомоги. Це дослідження мало на меті оцінити використання середнього індексу резистентності (СІР) для прогнозування гідронефрозу в пацієнтів, які госпіталізовані з приводу гострої ниркової коліки. Це проспективне дослідження було проведено на 100 пацієнтах, які були госпіталізовані до відділення невідкладної допомоги з проблемою односторонньої ниркової коліки (НК). При першому відвідуванні всім пацієнтам було виконано: 1). взято кров для лабораторних досліджень; 2). ЕКГ та кардіологічне дослідження; 3). рентген сечовивідних шляхів; 4). абдомінальне УЗД; 5). двобічне кольорове доплерівське ультразвукове дослідження (КДУД) з вимірюванням ІР нирок. На підставі інформації, зібраної в різний час під час експерименту, пацієнтів було розподілено на дві групи: групу з ознаками дилатації (група А) та групу з гідронефрозом (група Б). Отримані дані були статистично проаналізовані за допомогою програми SPSS версії 20. СІР із пороговим значенням 0,68 було найбільш точним (AUC:0,878), а також чутливим (90%) пороговим значенням для прогнозування розвитку гідронефрозу в пацієнтів з НК та нирковим каменем. Це граничне значення також забезпечило найвищі позитивні (94%) і негативні (76%) прогнози значення. КДУД з вимірюванням ІР – це простий і неінвазивний метод, який надає корисну інформацію про каміні обструкції сечовивідних шляхів у пацієнтів з односторонньою НК. У нашому дослідженні за допомогою цього методу вдалося успішно передбачити початок гострого розширення нирок. Це було зроблено з різними рівнями чутливості, специфічності, точності та діагностичної ефективності, які були вищими, ніж ультразвукове дослідження. Щоденне використання КДУД при відділенні невідкладної допомоги може покращити ультразвукове дослідження, особливо коли інші методи протипоказані. Наприклад, способи опромінення пацієнта (вагітність, алергія, ниркова недостатність тощо) або внутрішньовенне введення контрастних речовин (урографія та КТ).

Urinary tract stones are the most common causes of urinary tract obstruction, leading to patient hospitalization in the emergency room [1, 2].

The most common symptoms are severe pain in the abdomen and decreased urination, which can eventually lead to kidney failure [3]. Renal colic usually begins with pain in the lower back and reaches the hypochondrium or groin. This pain is usually periodic or wavy (due to ureteral peristalsis), but sometimes it is constant and continuous. Although it is one of the most severe pains a person can experience, it does not leave any permanent damage to the body. In certain cases, such as when the stone is very large, surgery may be necessary.

The main cause of renal colic is kidney stones, but it can have other causes, for example blood clot movement arisen from trauma or neoplastic diseases or urinary tract tumors or acute renal necrosis [4, 5]. Patients with renal colic (whatever the cause of the disease) are at risk for complete or partial acute renal obstruction. It ultimately leads to hydronephrosis and can worsen renal function over time. Ureteral stone disease is spreading around the world and the risk of it progressing in the Western Hemisphere is higher than in the Eastern. Reports indicate that the rate is 5-9% in Europe, 12% in Canada and 13-15% in the United States, while it is 1-5% in the Eastern Hemisphere. However, in some Asian countries, such as Saudi Arabia, it rises to 20.1% [6, 7]. Diagnosis of ureteral stones or acute renal colic is done with radiography that is mean US (Normal Ultrasound) and IVU (Intravenous Urography) [8]. However, the obstruction may occur in about 35% of cases without dilatating the pelvic system. In many cases, severe dilatation may occur without any obstruction. Often these cases are not detected by the USG; for detecting it, we should use color doppler evaluation. When there is acute renal obstruction, renal Doppler may show altered renal perfusion before dilatation of the pelvic system occurs [9]. Vasoactive factors (which first cause vasodilatation and then vasoconstriction) increase the internal resistance of the kidney. Finally, diastolic blood flow is reduced compared to systolic blood flow.

USG color Doppler measures these changes as the resistance index (RI) of arched arteries at the junction of the cortico-medullary or interlobar arteries. Thus, an increase in the RI index indicates obstruction without dilation. As for ultrasound, this method has a high sensitivity and specificity for detecting urinary tract obstruction. Sensitivity ranges from 91 to 92 percent (and from 94 to 97 percent when accompanied by a video recording of the urinary tract) and sensitivity (probably referring to feature text) is about 90 percent. However, its benefits (such as high reproducibility and lack of exposure to radiation or iodinated contrast agents, which make it safe even for pregnant women)

should be weighed against its limitations. Its limitations include the following; the results depend on the performance of the operator; results are affected by patient hydration; and the success rate in detecting stagnant stones is variable (38-4%), especially in patients who are very obese or patients who do not cooperate or those who have to bloat and have a large amount of flatulence [12, 13, 14]. Recent studies have shown that patients with RC should have a Doppler color photograph of their kidneys instead of a grayscale ultrasound. These studies also showed that the renal internal resistance index (RI) (which is one of the variables measured by this method) increases in the presence of hydronephrosis. It is clearly related to the severity and duration of urinary tract obstruction [10, 11, 15, 16]. This study aimed to evaluate the use of the mean resistance index (mRI) to predict hydronephrosis in patients admitted for acute renal colic.

MATERIALS AND METHODS OF RESEARCH

This prospective study was performed on 100 patients who were admitted to the emergency department with unilateral RC problem. The criteria for inclusion in this study are as follows:

- 1) The patient's history, clinical findings, and test results should prove that the person does not have nephropathy, obstructive uropathy, or metabolic diseases.
- 2) The patient's age is 50-20 years.
- 3) The patient has not received any medication before the first visit.
- 4) The onset of symptoms is less than 4 hours before enrollment in the study.

At the first visit, the following was done for all patients:

1. Blood was taken from them for laboratory studies;
2. ECG and cardiological test;
3. Plain film of the urinary tract;
4. Abdominal US;
5. And bilateral color doppler ultrasound (CDUS) with renal RI measurement.

All patients were treated with the same protocol, which included intramuscular injection of ketoprofen 100 mg every 12-24 hours, and intravenous hydration (2000 ml over 24 hours at a rate of 83 ml per hour) (and ciprofloxacin 500 mg daily). Six hours after the first visit, urinary ultrasound and CDUS were repeated with bilateral RI measurements. The RI was defined as “(peak systolic velocity minus end of diastolic velocity)/Systolic velocity peak”. All patients underwent CT of the urethra without contrast agents 48 to 60 hours after admission. Ultrasound was also performed for all patients which was done in the supine and lateral positions using the same devices as before (namely, Philips Visor HD and Convex Transformer 3-5: 5 MHz). CDUS measurements of RI

(excluding aliasing and other artifacts) were performed for each kidney's upper, middle, and lower parts between the lobar arteries and the arc arteries. If the average of the three numbers obtained in a kidney with symptoms was more than 0.70, it meant that there was an obstruction. This finding was referred as positive mean RI (mRI_p). Based on the information collected at different times during the experiment, patients were divided into two groups: the group that showed signs of dilatation (group A) and the group that did not show them (group B). The obtained data were analyzed statistically by SPSS version 20 to obtain the following:

- 1) Possible differences between groups A and B.
- 2) The relationship between the onset time of hydronephrosis and mRI_p.
- 3) Possible association between mRI_p and level, degree and duration of urinary tract obstruction.
- 4) Sensitivity, specificity, positive and negative prediction values and the efficiency of this method.

The research was approved by the ethics committee of Zahedan University of Medical Sciences and was conducted in accordance with the principles of bioethics set out in the WMA Declaration of Helsinki – “Ethical principles for medical research

involving human subjects” and “Universal Declaration on Bioethics and Human Rights” (UNESCO).” All patients filled informed consent forms.

RESULTS AND DISCUSSION

This study was performed on 100 people with unilateral renal colic who were referred to the emergency department of which 74 were male, and 26 were female. This study was performed on people aged 20-48 years and the mean age (± SD) was 34.7±7.92. According to the results, the mean (± SD) renal stone size was 8.65±3.16 mm, ranging from 3.8 mm to 21 mm. The results showed that 62% of the stones were located in the calyx of the kidney and 17% in the pelvic. Fifteen percent of the stones were in the upper 1/3 and 6% in the lower 1/3 of the ureter.

Urinary system status based

The second US in group A who previously had a normal US showed mild and moderate hydronephrosis in 56.7% and 3% of patients, respectively. On the other hand the group B who previously mostly showed mild hydronephrosis developed moderate hydronephrosis in 33.3% of cases (Table 1).

Table 1

Frequency distribution of urinary system status in the first and second ultrasound

Expansion status of the pilocalis system	First US	Second US in group A	Second US in group B
Normal	67 (67%)	27(40.3%)	0(0%)
Mild hydronephrosis	30 (30%)	38(56.7%)	22(66.7%)
Moderate hydronephrosis	3 (3%)	2(3%)	11(33.3%)
Severe hydronephrosis	0 (0%)	0	0(0)
Total	100 (100%)	67(100%)	33(100%)

The diagnostic performance of mRI

A mRI with a 0.68 cut off value was the most accurate(AUC:0.878), and Sensitive (90%) cut-off value for prediction of hydronephrosis development among patients presenting with RC and renal stone.

This cut-off value also provided the highest positive (94%) and negative (76%) predictive values. Mean while $\Delta RI \geq 0.06$ was the least accurate (74%), and sensitive (63%). Other diagnostic measures are mentioned in Table 2 and Figure.

Table 2

Sensitivity, specificity, positive and negative predictive value of mRI with different cut-off values and ΔRI

Pvalue	AUC	NPV	PPV	Spe	Sen	FN	FP	TN	TP	Cut -off value
0.001<	0.878	0.76	0.94	0.85	0.90	7	4	23	66	0.685
0.001<	0.857	0.69	0.94	0.85	0.86	10	4	23	63	0.7
0.001<	0.741	0.46	0.92	0.85	0.63	27	4	23	46	$\Delta RI \geq 0.06$
0.001<	0.816	0.58	0.93	0.85	0.70	16	4	23	57	$\Delta RI \geq 0.45$



Ultrasonography is one of the primary tools for diagnosing renal colic and renal obstruction. This method strongly depends on the anatomical criteria of pilocalis (PCS) system and ureteral dilatation, which is proximal to the level of dilatation.

The previous studies have reported that the sensitivity of US is >90% and its specificity is only 65-84% [18]. This is because US imaging may not be able to detect obstruction in some cases, especially when the obstruction is very small or mild. In individuals with calcaneal fornix or when the PCS system is clotted, better and more practical evidence of obstruction is provided by the doppler US technique, which provides more information about obstruction [19, 20]. Renal blood flow at the site of obstruction is phasic [21, 22, 23, 24]. Firstly the renal pelvic pressure is increased immediately as a response to obstruction which is followed by vasodilation [25-27].

However, when the obstruction is continued the hormonal regulatory system provide vasoconstriction. This vasoconstriction reduces renal blood flow to the obstruction site; as a result, the process of filtering urine is reduced, and the pressure the intra pelvic pressure returns to normal [21, 24, 28]. Measuring the resistance index helps diagnosing urinary tract obstruction, especially in patients with unilateral renal colic that has just started [18, 29, 30, 31]. RI is easy to measure, and is provided by the scanner itself. RI indirectly predicts resistance in the renal vessels. In a person with a kidney obstruction, this resistance increases. The reason for this is the pressure within the blood vessels [18, 32]. If the RI value is greater than 0.70, it indicates acute ureteral obstruction, as stated by Platt J. et al. and Sauvain J.L. [18, 33]. Since then, many other studies have been conducted to confirm these findings [18, 29, 30, 31].

The studies by Rodgers P.M. et al. and Platt J. et al. found that patients with acute renal obstruction had higher RI than those without them [18, 21]. It was also observed that the RI increased within 6 hours after admission to the hospital. All patients with hydronephrosis had an increased RI during this time. In this study, the sensitivity and specificity of Δ RI were evaluated to predict the onset of acute dilatation of the urinary system, which showed a high sensitivity, specificity and positive predictive value with a threshold of 0.06 and a low negative predictive value to predict obstructive hydronephrosis. The sensitivity and specificity of Δ RI with the proposed threshold of 0.045 for predicting hydronephrosis had a higher sensitivity and positive predictive value compared to Δ RI=0.06 and had a higher negative predictive

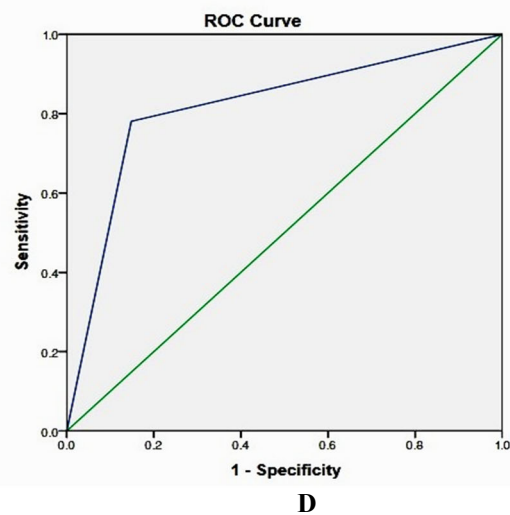
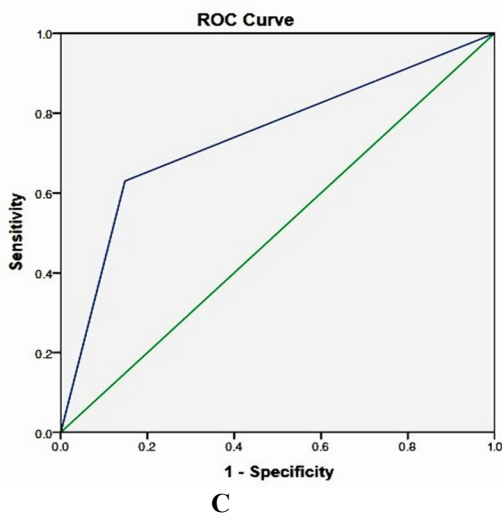
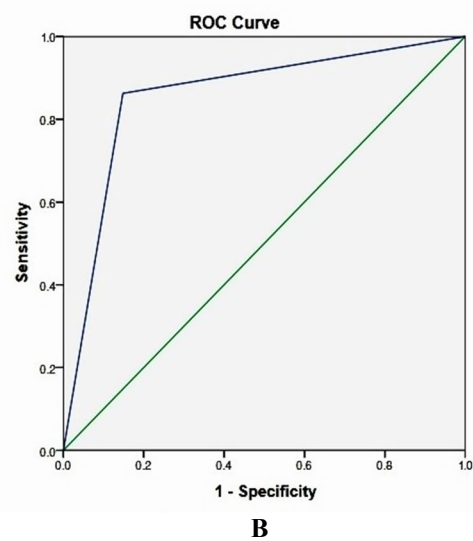
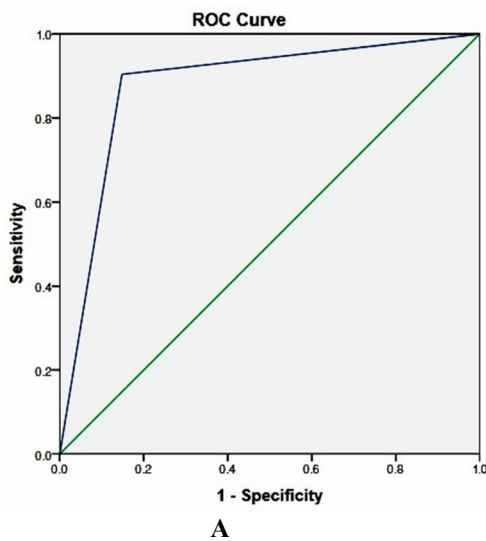
value, but their specificity was the same. These results were similar to Granta A. et al and Sayani M.A. et al. [14]. However, the low sensitivity of the Δ RI in this study may be due to included cases with partial ureteral obstruction. Sayani M.A. et al. showed that the sensitivity of RI in complete obstruction was 77.5% and its specificity was 84.3%. The sensitivity in cases with partial obstruction was 22.8%, and the specificity was 84.3%.

Therefore, it was concluded that the doppler test is not very good for detecting partial ureteral obstruction, but the sensitivity and specificity of RI in cases with complete obstruction were good (especially Δ RI). Granta A. et al. showed that intrarenal doppler is a method with high sensitivity and specificity for the diagnosis of acute renal colic obstruction in patients with renal insufficiency, who are pregnant or who are allergic to contrast agents.

Quantitative studies have also shown that mRI with color doppler is very useful for diagnosing renal obstruction, especially in acute cases with unilateral obstruction for 6-48 hours [19-29, 30, 31]. RI can estimate the degree of resistance in the renal blood vessels [27], but various studies have shown conflicting results. In the study of Tablin et al, the sensitivity of doppler ultrasound was only 44% and its specificity was 82%. In a study done by De Toledo L.S. et al., they found that an increase in mRI occurred, but it was for 24 hours after renal colic. These differences were due to the patient's clinical symptoms, which may not be related to anatomical obstruction et al. [34].

Due to the above positive results, the diagnosis of the disease using mRI has many limitations and is affected by many factors for example: age, plasma renin level, diabetes, blood pressure or heart disease. Other kidney disorders may increase the resistance index even if there is no obstruction [36]. It is been proved that mRI is less sensitive to detect partial obstruction than complete obstruction (some specific studies have concluded) [29, 31].

It has also been reported that the increase in mRI depends on the time elapsed after obstruction. As you can see in the present study, an increase in mRI was observed from 6-48 hours, which is consistent with the rest of the studies [19, 37]. Updenker and colleagues found that RI sensitivity increased 48 hours after the onset of symptoms. Plott and colleagues reported that more than 24 hours after the onset of symptoms, mRI is not much higher. However, Detoldo and colleagues stated, that the increased mRI lasted 24 hours. All of these differences depend on the clinical course of the obstruction.



Roc Curve with $mRI \geq 0.68$ (A), $mRI \geq 0.7$ (B), $\Delta RI \geq 0.06$ (C), and $\Delta RI \geq 0.45$ (D)

CONCLUSION

CDUS with RI measurement is an easy and non-invasive method that provides useful information about urinary tract obstruction stones in patients with unilateral RC. In our study, this method was able to predict successfully the onset of acute renal dilatation. This was done with different levels of sensitivity, specificity, accuracy and diagnostic efficiency. Daily use of CDUS in ED can improve ultrasound, especially when other methods are contraindicated. For example, the methods by which the patient is exposed to radiation (pregnancy, allergies, renal failure, etc.) or intravenous injection of contrast agents (urography and CT).

Contributors:

Hamid Dahmarde – conceptualization, methodology, formal analysis, writing – review & editing;

Faramarz Fazeli – investigation, data curation, writing – review & editing, supervision.

Funding. This research received no external funding.

Conflict of interests. The authors declare no conflict of interest.

REFERENCES

- Hall J, Linton KD. Obstruction of the upper and lower urinary tract. Surgery (Oxford). 2008;26:197-202. doi: <https://doi.org/10.1016/j.mpsur.2008.03.007>
- Pepe P, Motta L, Pennisi M, Aragona F. Functional evaluation of the urinary tract by color-Doppler

- ultrasonography (CDU) in 100 patients with renal colic. Eur J Radiol. 2005;53:131-5. doi: <https://doi.org/10.1016/j.ejrad.2004.01.014>
- Rishi N, Anil KS, Kaza RCM, Anand VJ. The obstructed kidney. Indian J Surg. 2005;67:21-8.

4. Thomas A, Andrienne R. Excruciating flank pain: "acute renal colic". *Rev Med Liege*. 2004;59:215-20.
5. Fauci AS, Braunwald E, Isselbacher KJ, Wilson JD, Martin JB, Kasper DL, et al. *Harrison's principles of internal medicine*. 14th ed. New York, NY: McGraw-Hill Book Co; 1998.
6. Ramello A, Vitale C, Marangella M. Epidemiology of nephrolithiasis. *J Nephrol*. 2000;13:S65-70.
7. Robertson WG, Hughes H. Epidemiology of urinary stone disease in Saudi Arabia. In: Ryall R, Bais R, Marshall VR, Rofe AM, Smith LH, Walker VR, eds. *Urolithiasis 2*. Plenum Press, New York: London; 1994:453-5. doi: https://doi.org/10.1007/978-1-4615-2556-1_174
8. Tamm EP, Silverman PM, Shuman WP. Evaluation of the patient with flank pain and possible ureteral calculus. *Radiology*. 2003;228:319-29. doi: <https://doi.org/10.1007/s00240-007-0116-2>
9. Onur MR, Cubuk M, Andic C, Kartal M, Arslan G. Role of resistive index in renal colic. *Urol Res*. 2007;35:307-12.
10. Leipe K, Taut-Sack H. Can renal Doppler sonography replace diuretic radionuclide renography in infants with hydronephrosis? *Turk J Pediatr*. 2006;48:221-7. doi: <https://doi.org/10.1046/j.1464-410x.1999.00946.x>
11. Shokeir AA, Abdulmaaboud M. Resistive index in renal colic: a prospective study. *BJU international*. 1999 Mar 1;83(4):378-82. doi: <https://doi.org/10.1136/emj.2005.028589>
12. Kartal M, Eray O, Erdogru T, Yilmaz S. Prospective validation of a current algorithm including bedside US performed by emergency physicians for patients with acute flank pain suspected for renal colic. *Emergency medicine journal*. 2006 May 1;23(5):341-4.
13. aza Perez JA, Ferrer JF, Urdangarain OO, Nunez AB. Renal colic at emergency departments. Epidemiologic, diagnostic and etiopathogenic study. *Archivos espanoles de urologia*. 2010 Apr 1;63(3):173-87. doi: <https://doi.org/10.2147/IJNRD.S27628>
14. Sayani MA, Shazlee K, Hamid RS, Hamid K. Functional evaluation of the urinary tract by duplex Doppler ultrasonography in patients with acute renal colic. *International journal of nephrology and renovascular disease*. 2012;5:15. doi: <https://doi.org/10.1017/S1481803500012240>
15. Edmonds ML, Yan JW, Sedran RJ, McLeod SL, Theakston KD. The utility of renal ultrasonography in the diagnosis of renal colic in emergency department patients. *Canadian Journal of Emergency Medicine*. 2010 May;12(3):201-6.
16. Kavakli HS, Kokter A, Yilmaz A. Diagnostic value of renal resistive index for the assessment of renal colic. *Singapore medical journal*. 2011 Apr 1;52(4):271. doi: <https://doi.org/10.1007/s003300050568>
17. Opdenakker L, Oyen R, Vervloessem I, Goethuys H, Baert AL, Baert LV, Marchal G. Acute obstruction of the renal collecting system: the intrarenal resistive index is a useful yet time-dependent parameter for diagnosis. *European radiology*. 1998 Sep;8(8):1429-32. doi: <https://doi.org/10.1148/radiology.186.3.8430174>
18. Platt JF, Rubin JM, Ellis JH. Acute renal obstruction: evaluation with intrarenal duplex Doppler and conventional US. *Radiology*. 1993;186:685-8. doi: <https://doi.org/10.1148/radiology.171.2.2649925>
19. Platt JF, Rubin KM, Ellis JH, DiPietro M. Duplex Doppler US of the kidney: Differentiation of obstructive from non-obstructive dilatation. *Radiology*. 1989;171:515-7. doi: <https://doi.org/10.1046/j.1464-410x.2000.00583.x>
20. Webb JA. Ultrasonography and Doppler studies in the diagnosis of renal obstruction. *BJU Int*. 2000;86:25-32. doi: <https://doi.org/10.1259/0007-1285-65-771-207>
21. Rodgers PM, Bates JA, Irving HC. Intrarenal Doppler ultrasound studies in normal and acutely obstructed kidneys. *Br JRadiol*. 1992;65:207-12.
22. Moody TE, Vaughan ED Jr, Gillenwater JY. Relationship between renal blood flow and ureteral pressure during 18 hours of total unilateral occlusion: implications for changing sites of increased renal resistance. *Invest Urol*. 1975;13:246-51. doi: [https://doi.org/10.1016/S0022-5347\(17\)43297-6](https://doi.org/10.1016/S0022-5347(17)43297-6)
23. Ryan PC, Macer KP, Murphy B. Experimental partial obstruction: pathophysiological changes in upper tract pressures and renal blood flow. *J Urol*. 1987;138:674-8. doi: <https://doi.org/10.7863/jum.1996.15.9.613>
24. Lee HJ, Kim SH, Jeong YK. Doppler sonographic resistive index in obstructed kidneys. *J Ultrasound Med*. 1996;15:613-8.
25. Klahr S. Pathophysiology of obstructive nephropathy: a 1991 update. *Semin Nephrol*. 1991;11:156-68.
26. Croan JJ. Acute urinary tract obstruction in adults. In: *RSNA Categorical Course in Genitourinary Radiology*. Oak Brook, IL: Radiological Society of North America; 1994:103-108. doi: [https://doi.org/10.1016/S0033-8389\(22\)00694-7](https://doi.org/10.1016/S0033-8389(22)00694-7)
27. Platt JF. Urinary obstruction. *Radiol Clin North Am*. 1996;34:1113-29.
28. Vaughan ED Jr, Sorenson EJ, Gillenwater JY. The renal hemodynamic response to chronic unilateral complete ureteral occlusion. *Invest Urol*. 1970;8:78-90. doi: <https://doi.org/10.1046/j.1464-410x.1999.00946.x>
29. Shokeir AA, Abdulmaaboud M. Resistive index in renal colic: a prospective study. *BJU Int*. 1999;83:378-82. doi: <https://doi.org/10.1007/s003300050568>
30. Opdenakker L, Oyen R, Vervloessem I, Goethuys H, Baert AL, Baert LV, et al. Acute obstruction of the renal collecting system: the intrarenal resistive index is a useful yet time-dependent parameter for diagnosis. *Eur Radiol*. 1998;8:1429-32. doi: [https://doi.org/10.1016/S0022-5347\(05\)66431-2](https://doi.org/10.1016/S0022-5347(05)66431-2)
31. Shokeir AA, Abdulmaaboud M. Prospective comparison of nonenhanced helical computerized tomography and Doppler ultrasonography for the diagnosis of renal colic. *J Urol*. 2001;165:1082-4. doi: [https://doi.org/10.1016/S0022-5347\(05\)66316-1](https://doi.org/10.1016/S0022-5347(05)66316-1)
32. Rawashdeh YF, Djurhuus JC, Mortensen J, Hørlyck A, Frokiaer J. The intrarenal resistive index as a pathophysiological marker of obstructive uropathy. *J Urol*. 2001;165:1397-404.
33. Sauvain JL, Pierrat V, Chambers R, Bui Xuan P, Palascak P, Boursheid D, et al. Echography and pulsed Doppler of the arteries of the renal parenchyma in obstructive syndromes and dilatation of the excretory

cavities of the kidney. J Radiol. 1989;70:389-98.
doi: [https://doi.org/10.1016/0720-048X\(96\)01055-8](https://doi.org/10.1016/0720-048X(96)01055-8)

34. De Toledo LS, Martinez-Berganza AT, Cabrejas CR, de Gregorio AMA, Cortina PP, Saldias RL. Doppler duplex ultrasound in renal colic. Eur J Radiol. 1996;23:143-8.

doi: <https://doi.org/10.2147/IJNRD.S27628>

35. Sayani R, Ali M, Shazlee K, Hamid RS, Hamid K. Functional evaluation of the urinary tract by duplex Doppler ultrasonography in patients with acute

renal colic. Int J Nephrol Renovasc Dis. 2012;5:15e21.
doi: <https://doi.org/10.1023/B:UROL.0000020302.65486.f8>

36. Haroun A. Duplex Doppler sonography in patients with acute renal colic: prospective study and literature review. Int Urol Nephrol. 2003;35:135e40.
doi: <https://doi.org/10.1016/j.jus.2012.10.003>

37. Piazzese EMS, Mazzeo GI, Galipo S, Fiumara F, Canfora C, Angiom LG. The renal resistive index as a predictor of acute hydronephrosis in patients with renal colic. J Ultrasound. 2012;15:239e246.

Стаття надійшла до редакції
13.05.2022

