

World. USA: IHCW, 2016 [cited 2019 Apr 24]. URL: http://www.ihcworld.com/_protocols/special_stains/nissl.htm

13. Shkodina A. D., Hrinko R. M., Starchenko I. I. Modern conception as to the functional morphology of the olfactory system and its changes under the influence of some exogenous pollutants. *The Medical and Ecological Problems*. 2019. Vol. 23, No. 3-4. P. 37-40. DOI: <https://doi.org/10.31718/mep.2019.23.3-4.09>

14. Šijan Gobeljić M., Milić V., Pejnović N., Damjanov N. Chemosensory dysfunction, Oral disorders and Oral health-related quality of life in patients with primary Sjögren's syndrome: comparative cross-sectional study. *BMC Oral Health*. 2020. 3 Jul. (Vol. 20, No. 1). P. 187. DOI: <https://doi.org/10.1186/s12903-020-01169-5>

15. Streptococcus pneumoniae infection regulates expression of neurotrophic factors in the olfactory bulb and cultured olfactory ensheathing cells / S. Ruiz-Mendoza et al. *Neuroscience*. 2016. 11 Mar. (Vol. 317). P. 149-161. DOI: <https://doi.org/10.1016/j.neuroscience.2016.01.016>

16. Unsupervised method for normalization of hematoxylin-eosin stain in histological images / T. A. A. Tosta et al. *Comput Med Imaging Graph*. 2019. Oct. (Vol. 77). P. 101646. DOI: <https://doi.org/10.1016/j.compmedimag.2019.101646>

17. Yuan J., Li Q., Niu R., Wang J. Fluoride exposure decreased learning ability and the expressions of the insulin receptor in male mouse hippocampus and olfactory bulb. *Chemosphere*. 2019. Vol. 224. P. 71-76. DOI: <https://doi.org/10.1016/j.chemosphere.2019.02.113>

The article was received
2020.01.23



UDC 616.314.21/22-007.24-089.23

<https://doi.org/10.26641/2307-0404.2021.2.234633>

B.M. Mirchuk,
Y.V. Maksymov*

ORTHODONTIC TREATMENT OF SECONDARY DEFORMATIONS IN ADULT PATIENTS WITH DEFECTS OF DENTITION

Danylo Halytsky Lviv National Medical University

Department of Orthodontics

Pekarska st., 69, Lviv, 79010, Ukraine

e-mail: mirchukb@gmail.com

*Zaporizhzhia State Medical University**

Department of the therapeutic, orthopedic and pediatric dentistry

Mayakovsky ave., 26, Zaporizhzhia, 69000, Ukraine

e-mail: maksymovuan@gmail.com

*Львівський національний медичний університет ім. Данила Галицького
кафедра ортодонції*

(зав. – д. мед. н., доцент Н.Л. Чухрай)

вул. Пекарська, 69, Львів, 79010, Україна

*Запорізький державний медичний університет**

кафедра терапевтичної, ортопедичної та дитячої стоматології

(зав. – д. мед. н., доцент О.В. Возний)

пр. Маяковського, 26, Запоріжжя, 69000, Україна

Цитування: *Медичні перспективи*. 2021. Т. 26, № 2. С. 104-110

Cited: *Medicni perspektivi*. 2021;26(2):104-110

Key words: *primary dental implant, secondary deformations of dentition, dentition defects, deficit of space for artificial teeth, segmental bracket system, torque of teeth, angulation of teeth*

Ключові слова: *тимчасовий денціальний імплантат, вторинні деформації зубних рядів, дефекти зубних рядів, дефіцит місця для штучних зубів, сегментарна брекет-система, торк зубів, ангуляція зубів*

Ключевые слова: *временный денціальний імплантат, вторичные деформации зубных рядов, дефекты зубных рядов, дефицит места для искусственных зубов, сегментарная брекет-система, торк зубов, ангуляция зубов*

Abstract. Orthodontic treatment of secondary deformations in adult patients with defects of dentition. Mirchuk B.M., Maksymov Y.V. *In the presence of dentition defects there is a complex of morphological, aesthetic and functional changes that significantly complicate the process of diagnosis and treatment of this pathology. Dentition defects, combined with various dental anomalies and deformations very often impede rational prosthetics and at times make it impossible at all. The aim is to increase the effectiveness of orthodontic treatment of secondary deformations in patients with dentition defects by using primary dental implants as an additional skeletal support. For clinical evaluation of the effectiveness of treatment of secondary deformations in 20 patients with partial dentition defects there was performed orthodontic treatment using a straight arc technique with metal braces of the Roth system and primary detailed one-component implants as an additional skeletal support. On the diagnostic models of the jaws, the meso-distal dimensions of the lost teeth and their possible position in the dentition were determined, the shape of the dentition by methods of Pon and Korkhaus, the position of the teeth in the area of dentition defects was analyzed and the jigs of occlusion according to Andrews were defined. The use of primary dental implants as an additional skeletal support in the area of dentition defects makes it possible to control the rotation of the teeth and at the same time to use orthodontic forces of different intensity during their distal or mesial movement. As a result of orthodontic treatment of secondary deformations, we managed to achieve positive changes in the normalization of angles of dental inclination that limit the defect in patients with dentition defects. Along with the normalization of the angles of dental inclination (torque and angulation) which limit dentition defects we have noticed an increase in the distance between these teeth, which allows to restore dentition defect with dentures, better corresponding to the size of the lost teeth. Important, in our opinion, is the possibility, when using a primary dental implant as an additional skeletal support, to use the technique of segmental braces. The use of primary dental implants in the area of the dentition defect as an additional skeletal support makes it possible to restore angulation and torque of the teeth, which limit the defect, using orthodontic forces of different intensity. As a result of orthodontic treatment of secondary deformations, the distance between teeth limiting dentition defects on the upper jaw increased on average by 2.39 mm ($p < 0.001$) and on the lower jaw – by 2.57 mm ($p < 0.001$).*

Реферат. Ортодонтичне лікування вторинних деформацій у дорослих пацієнтів із дефектами зубних рядів. Мірчук Б.М., Максимов Я.В. *При наявності дефектів зубних рядів виникає комплекс морфологічних, естетичних та функціональних змін, що значно ускладнюють процес діагностики та лікування цієї патології. Дефекти зубних рядів, у поєднанні з різноманітними зубоцелепними аномаліями та деформаціями, дуже часто перешкоджають проведенню раціонального протезування, а деколи роблять його взагалі неможливим. Мета – підвищення ефективності ортодонтичного лікування вторинних деформацій у пацієнтів з дефектами зубних рядів шляхом використання тимчасових денціальних імплантатів в якості додаткової скелетної опори. Для клінічної оцінки ефективності лікування вторинних деформацій 20 пацієнтам з частковими дефектами зубних рядів ортодонтичне лікування проводилось технікою прямої дуги з використанням металевих брекетів системи Рот та тимчасових денціальних однокомпонентних імплантатів в якості додаткової скелетної опори. На діагностичних моделях щелеп визначено мезіодистальні розміри втрачених зубів та їх можливе розташування в зубному ряді, проведено аналіз форми зубних рядів за Поном і Коркхаузом, положення зубів у ділянці дефектів зубних рядів, визначено ключі оклюзії Ендрюса. Застосування тимчасових денціальних імплантатів в якості додаткової скелетної опори в ділянці дефектів зубних рядів дозволяє контролювати ротацію зубів і одночасно використовувати різні величини ортодонтичних сил під час їх дистального чи мезіального переміщення. У результаті ортодонтичного лікування вторинних деформацій у пацієнтів з дефектами зубних рядів вдалося досягнути позитивних змін щодо нормалізації кутів нахилу зубів, які обмежують дефект. Разом із нормалізацією кутів нахилу (торку й ангуляції) зубів, які обмежують дефекти зубних рядів, ми відмітили і збільшення відстані між цими зубами, що дозволяє замінити дефект зубного ряду протезами, які краще відповідають розмірам втрачених зубів. Важливою, на нашу думку, є можливість, при застосуванні тимчасового денціального імплантанту в якості додаткової скелетної опори, використання техніки сегментарних брекет-систем. Застосування тимчасових денціальних імплантатів у ділянці дефекту зубних рядів в якості додаткової скелетної опори дозволяє відновити ангуляцію і торк зубів, які обмежують дефект, використовуючи ортодонтичні сили різної величини. У результаті ортодонтичного лікування вторинних деформацій відстань між зубами, що обмежують дефекти зубних рядів, на верхній щелепі збільшилась у середньому на 2,39 мм ($p < 0.001$), а на нижній щелепі – на 2,57 мм ($p < 0.001$).*

Partial tooth loss is one of the most common forms of dento-maxillary defects in adulthood. The number of patients with dentition defects in the total population of Ukraine ranges from 70% to 95%. [1, 3, 4, 8]. In young and middle-aged people bounded dentition defects are much more common as compared with the distally borderless defects, and by localization, bounded dentition defects prevail in

the posterior triangle of neck in the absence of one or two teeth [7].

At the same time, many authors pay attention to the increase in the prevalence of secondary dento-maxillary deformations, the cause of which is a decrease in the height of the clinical crowns of masticatory teeth due to their destruction by the carious process and dentition defects which make up

from 4.8% to 54.5% [11]. As a result of dentition defects presence, a complex of morphological, aesthetic and functional changes arises, which significantly complicate the process of diagnosis and treatment of this pathology. Dentition defects combined with a variety of dento-maxillar anomalies very often impede rational prosthetics, and sometimes make it impossible at all.

The aim of the study is to increase the effectiveness of orthodontic treatment of secondary deformations in patients with dentition defects by using primary dental implants as an additional skeletal support.

MATERIALS AND METHODS OF RESEARCH

For clinical evaluation of the effectiveness of treatment of secondary deformations, 20 patients with partial dentition defects underwent orthodontic treatment by straight-wire technique with the use of metal braces of Roth system and primary detailed one-component VKtemp implants of the native producer VITAPLANT® (“Vitadent Ltd” Ukraine, Zaporizhzhia) as an additional skeletal support.

The primary one-component VKtemp implant has a root shape and angulation thread of 15 degrees. The diameter is 2.5 mm and the length is 10 mm, 12 mm, 14 mm or 16 mm. Depending on the type of bone, pilot twistdrills with a diameter of 2.0 mm and 1.5 mm are used, both classical and transgingival implantation is possible. Twistdrills are tapped in the area of the defect using a surgical template. For the fixing of braces on primary dental implants, plastic crowns with supporting orthodontic elements (rings or braces) are made [6].

All patients were diagnosed, treatment plan was made and prosthetic treatment of defects with fixed or non-fixed dentures, orthodontic treatment of secondary deformations was proposed.

In each patient, before treatment and after, C-silicone imprints of the maxilla and mandible were made, gypsum diagnostic models were casted. On the diagnostic models of the jaws the mesodistal dimensions of the lost teeth and their possible position in the dentition were determined [12], the analysis of the shape of denture according to Pont [14] and Korkhaus [14], the position of the teeth in the area of dentition defects were analyzed, Andrews occlusion jigs were defined [14].

The results of the research were processed by modern statistical methods of analysis on a personal computer using the standard suite of programs Microsoft Office 2010 (Microsoft Excel [5]) and "STATISTICA® for Windows 6.0" [10] (StatSoft Inc., USA, license 46 # AXXR712D833214FAN5) based on the Windows 10 operating system, and by using the NumPy (BSD License), SciPy (BSD

License), pandas (BSD License), pandas-profiling (MIT License) libraries, to visualize the processed data, the matplotlib library (BSD License) for Python programming language was used [9].

The hypothesis of the normality of the distribution of the studied indicators was tested using the Shapiro-Wilk criterion and the Kolmogorov-Smirnov consistency criterion. The Kolmogorov – Smirnov homogeneity criterion was used to test the hypothesis that two independent samples belong to one distribution law.

Arithmetic mean (M) and standard error ($\pm m$) were calculated. The statistical significance of the intergroup differences according to the data obtained was established using the parametric Student's t-test (*) and the non-parametric U-Whitney-Mann test (p ***) [2].

The results obtained were compared between the median and the quartile range of Me (Q1; Q3).

We used 3 levels of statistical significance of the differences in the study results – $p < 0.05$; $p < 0.01$; and $p < 0.001$.

Studies have been conducted in compliance with ethical standards of scientific medical research involving human beings.

RESULTS AND DISCUSSION

Dentition defects were diagnosed according to Kennedy classification [13]: on the maxilla – there were 5.0% of patients with class I, 65.0% – with class III and 5.0% – with class IV; on the mandible – 10.0% of patients with class I, 16.0% – with class II, 70.0% – with class III.

The position of the teeth in the area of defects by Andrews occlusion jigs was determined: angulation (II jig) and torque (III jig) disorder was diagnosed in all (100%) patients with dentition defects, 55.0% – without dental turn (IV jig) both on the maxilla and mandible, the absence of interdental space (V jig) on the maxilla was detected in 50.0% of patients and on the mandible – in 30.0%.

As a result of orthodontic treatment of secondary deformations in patients with dentition defects, positive changes regarding normalization of angulation of teeth that limit the defect have been achieved. Due to distalization of teeth (teeth that distally limit defect), the mesio-distal angulation decreased on average by $4.15 \pm 0.5^\circ$ ($p < 0.05$) on the maxilla and $12.89 \pm 0.5^\circ$ ($p < 0.001$) on the mandible) as compared to the measurements made before treatment. Mesialization of the teeth that mesially limit the defect caused the increase in the angulation angle on average by $4.66 \pm 0.5^\circ$ ($p < 0.05$) on the maxilla, by $7.56 \pm 0.5^\circ$ ($p < 0.001$) – on the mandible) as compared to the measurements made before treatment (Table 1).

Table 1

Average values of reduction and increase in the torque of teeth in the area of dentition defect (M±m)

Value of change of torque	Before treatment		After treatment	
	maxilla	mandible	maxilla	mandible
Reduction	-7.50±0.5°	-8.67±0.5°	-2.81±0.5°	-3.40±0.5°
Increase	+7.14±0.5°	+12.70±0.5°	+2.59±0.5°	+4.98±0.5°
Significance of difference	5.87±1.07 – 8.77±1.33	14.21±1.48 – 10.29±1.26	2.07±0.28 p<0.001 – 3.54±0.62 p<0.01	5.16±0.57 – 3.82±0.49 p<0.001

A similar positive effect was noted on determining vestibulo-oral angle (torque) of the angulation, which limits dentition defect. Thus, at an excessive value of torque, reduction in the angulation of teeth was on average at 4.55±0.5° (p<0.01) on the maxilla and at 7.72±0.5° (p<0.001) on the

mandible) and at a reduced value of the torque, increase was 4.69±0.5° (p<0.01) on the maxilla and 5.27±0.5° (p<0.001) on the mandible, as compared with values before the onset of orthodontic treatment (Table 2).

Table 2

The average values of reduction and increase of angulation of teeth in the area of dentition defect (M±m)

Value of change of torque	Before treatment		After treatment	
	maxilla	mandible	maxilla	mandible
Reduction	-7.79±0.5°	-12.72±0.5°	-3.13±0.5°	-5.16±0.5°
Increase	+8.12±0.5°	+21.03±0.5°	+3.97±0.5°	+8.14±0.5°
Significance of difference	9.0±2.41 – 10.0±1.89	14.47±2.23 – 26.59±2.15	4.08±1.18 – 5.0±1.14 p<0.05	5.79±1.04 – 10.53±0.98 p<0.001

Along with the normalization of angulation (torque and angulation) of the teeth which limit dentition defects, we noticed an increase in the

distance between these teeth, this allows to replace dentition defect with the dentures which correspond better to the size of the teeth lost (Table 3).

Table 3

Deficit of space for artificial teeth in the area of dentition defect (M±m)

Before treatment		After treatment	
maxilla	mandible	maxilla	mandible
-3.51±0.71 mm	-4.0±0.48 mm	-1.12±0.29 mm p<0.001	-1.43±0.24 mm p<0.001

After orthodontic treatment, the distance between the teeth that limit the dentition defect on the maxilla increased on average by 2.39 mm ($p < 0.001$) and on the mandible – by 2.57 mm ($p < 0.001$).

The use of primary dental implants as an additional skeletal support in the area of dentition defects allows to control the rotation of the teeth and at the same time to use different values of orthodontic forces during their distal or mesial movement (Fig. 1). Thus, for mesialization of teeth (in most cases of premolars) smaller forces (light or medium opening springs) than for distalisation of molars

(medium or strong opening springs) were used. In addition, it is known that tooth mesialization is faster than distalization, so when reaching the desired position of the mesially located tooth we could stabilize its position and continue the distalization of the tooth, where a primary dental implant served as a support. In no case, as with the simultaneous use of springs of different force for mesialization and distalization of the teeth, and for the migration of only one tooth (distally or mesially), we did not observe the change of position of the primary dental implant, which served as an additional skeletal support.

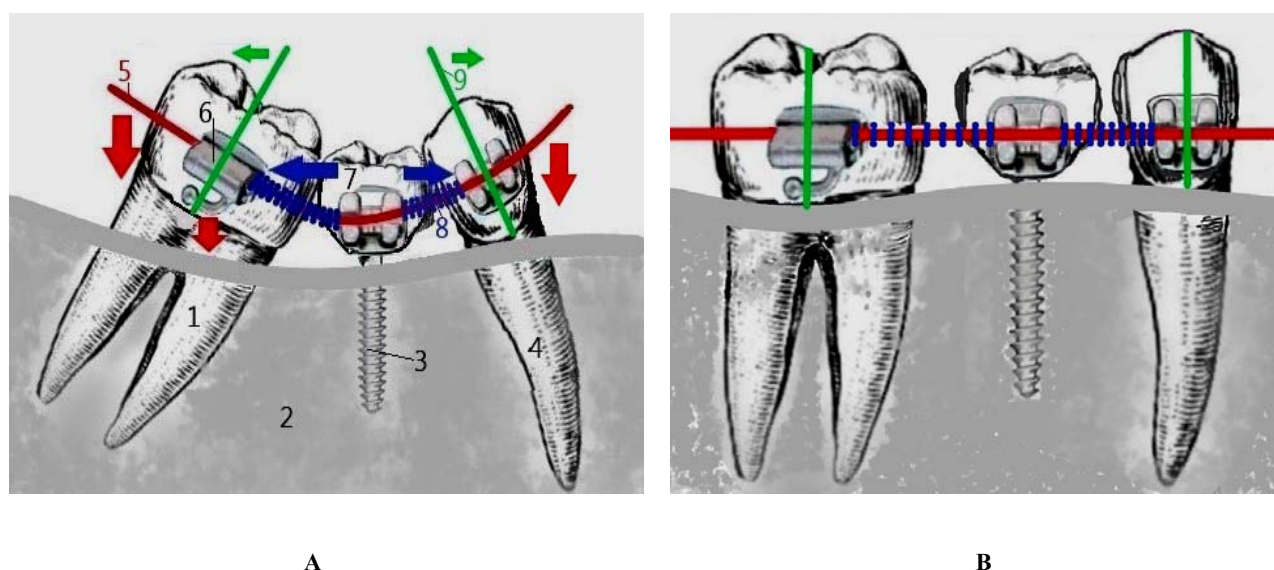


Fig. 1. Scheme of primary dental implant use. A - before treatment. B - after treatment

Conventional symbols on the scheme: 1 – the second right permanent molar tooth; 2 – osseous tissue of jaw; 3 – primary dental implant; 4 – the second right premolar tooth; 5 – orthodontic arch; 6 – supporting orthodontic element (brace); 7 – artificial plastic crown; 8 – opening spring; 9 – axis of crown portion of tooth.

In case of impaired angulation of the teeth that limit dentition defect, the use of a primary dental implant as an additional skeletal support together with bracket systems ensures the restoration of the correct position of the premolar teeth within 4-6 weeks, molar teeth – within for 8-9 weeks. Distalization of the molar teeth lasts 12.5 weeks on average, and mesialization of premolar teeth – 7.5 weeks.

It is of importance, in our opinion, is a possibility when using a temporary dental implant as an additional skeletal support, to use the technique of

segmental bracket-systems (fixing braces on several teeth on the side of defect) in patients with deficit of space in the area of defect by changing the position of the teeth (mainly disorders of torque and angulation), which limit dentition defect while retaining the signs of physiological occlusion (Fig. 2).

During the entire period of orthodontic treatment there were no cases of change of position or disintegration of the primary implant. We also did not observe inflammatory processes around implants (peri-implants).

After the completion of active orthodontic treatment and restoration of the dentition defect, various methods of retention were used: increasing the size of the plastic crown (by photopolymer directly in the oral cavity, or making a new primary plastic crown) until close contact with adjacent teeth; manufacture of removable retentive apparatus with artificial teeth in the area of the dentition defect.

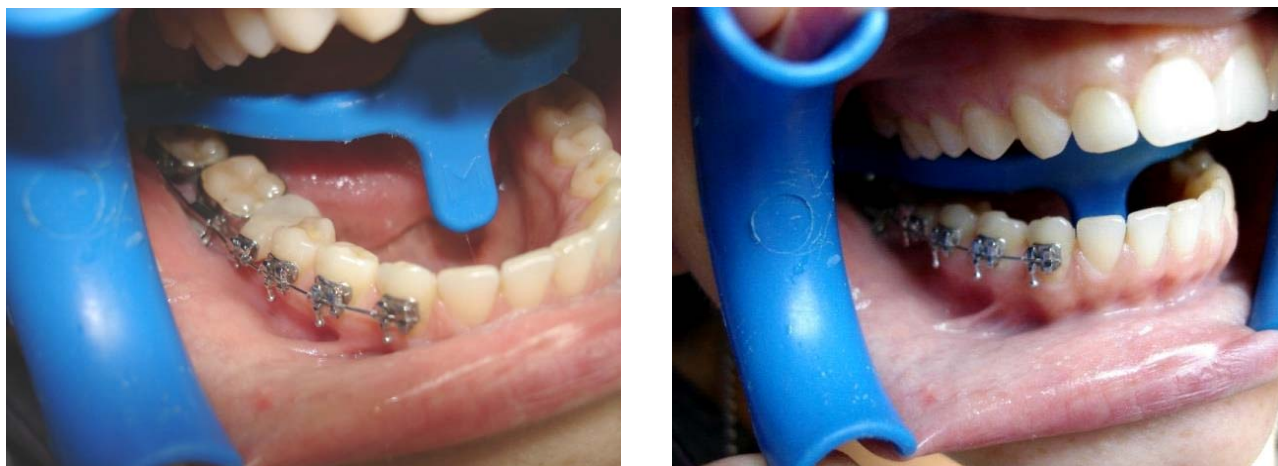

Fig. 2. Segmental bracket-system, temporary dental implant with plastic crown and brace in place of the extracted 46th tooth

CONCLUSIONS

1. The use of primary dental implants in the area of the dentition defect as an additional skeletal support allows to restore the angulation and torque of the teeth, which limit the defect, using orthodontic forces of different intensity.

2. As a result of orthodontic treatment of secondary deformations, the distance between the teeth

that limit dentition defects on the maxilla increased on average by 2.39 mm ($p < 0.001$) and on the mandible – by 2.57 mm ($p < 0.001$).

Conflict of interests. The authors declare no conflict of interest.

REFERENCES

1. Beliaiev EV. [Features of diagnosis, treatment and rehabilitation of secondary deformations of the dento-maxillofacial system]. *The world of medicine and biology*. 2015;4(53):151-6. Ukrainian. Available from: <https://womab.com.ua/ua/smb-2015-04-1/5691>
2. Korneyev AA, Krichevets AN. [Terms for applicability of Student's t-test and Whitney-Mann test]. *Psychological Journal*. 2011;32(1):97-110. Russian. Available from: <http://naukarus.com/usloviya-primenimosti-kriteriev-studenta-i-manna-uitni>
3. Korol MD, Nidzelskyi MYa, Korol DM, Dorubets AD, editors. [Secondary deformations of dental rows]. Poltava: Astreia; 2016. p. 150. Ukrainian.
4. Kutsevlyak VI. [Orthodontic surgery]. Kharkiv: NTMT; 2017. p. 275. Russian.
5. Lapach SN, Chubenko AV, Babich PN. [Statistical methods in medical-biological research with the use of Excel]. Kyiv: Morion; 2001. p. 408. Ukrainian. Available from: <https://www.twirpx.com/file/1466887/>
6. Mirchuk BM, Maksymov YaV. [The use of primary dental implants as a skeletal support for orthodontic treatment of secondary deformations in patients with dentition defects in the lateral areas]. *East European Scientific Journal*. 2019;9(49 part 2):19-25. Ukrainian. Available from: https://eesa-journal.com/wp-content/uploads/EESA_september_part_2.pdf
7. Mirchuk BM, Maksymov YaV. [Frequency of defects of dental rows among adult patients of the city of Zaporozhye who have sought prosthetic treatment]. *Topical issues of pharmaceutical and medical science and practice*. 2017;10(1):102-6. Ukrainian. doi: <https://doi.org/10.14739/2409-2932.2017.1.93452>
8. Pekhno VV. [Prevalence of defects of dental rows in pregnant women]. *Bulletin of problems of biology and medicine*. 2016;2(134 Suppl 4):270-2. Ukrainian. Available from: <https://cyberleninka.ru/article/n/poshirenist-defektiv-zubnih-ryadiv-u-vagitnih/viewer>
9. Plas JB. [Python for complex tasks. Science of data and computerized learning]. Sankt-Peterburg: Piter; 2018. p. 576. Russian. Available from: <https://habr.com/ru/company/piter/blog/339766/>
10. Rebrova OYu. [Statistical analysis of medical data. Usage of package program STATISTICA]. Moskva: Media Sphere; 2002. p. 312. Russian. Available from: <https://www.twirpx.com/file/1440496/>
11. Rivis OYu. [Apparatus and surgical treatment of dentition anomalies and deformations with the use of skeletal support on mini-implants (experimental clinical study)]. [abstract dissertation]. Uzhgorod: Uzhhorod. nat. university; 2017. p. 20. Ukrainian.
12. Mirchuk BM, Zavoiko OB, Maksymov YaV, inventor; [The method of determining the mesiodistal size

of the lost teeth in patients with defects of the dental rows]. Ukraine patent for utility model No. 119712. 2017 Oct 10. Ukrainian.

13. Deepak Nallaswamy. Textbook of Prosthodontics. JP: Medical Ltd; 2017 Sept;30:1550. Available from:

<https://books.google.com.ua/books?id=DLpEDwAAQBAJ&printsec=frontcover&hl=ru#v=onepage&q&f=false>

14. Nikhil Marwah. Textbook of Pediatric Dentistry. New Delhi, London, Panama: Jaypee Brothers Medical Publishers Ltd; 2017. p. 1120.

СПИСОК ЛІТЕРАТУРИ

1. Беляев Е. В. Особливості діагностики, лікування і реабілітації вторинних деформацій зубощелепової системи. *Світ медицини та біології*. 2015. Т. 53, № 4. С. 151-156.

URL: <https://womab.com.ua/ua/smb-2015-04-1/5691>

2. Корнеев А. А., Кричевец А. Н. Условия применимости критериев Стьюдента и Манна-Уитни. *Психологический журнал*. 2011. Т. 32, № 1. С. 97-110. URL: <http://naukarus.com/usloviya-primenimosti-kriteriev-studenta-i-manna-uitni>

3. Король М. Д., Нідзельський М. Я., Король Д. М., Дорубець А. Д. Вторинні деформації зубних рядів: монографія. Полтава: Астрєя, 2016. 150 с.

4. Куцевляк В. И. Ортодонтическая хирургия. Харьков: «НТМТ», 2017. 275 с.

5. Лапач С. Н., Чубенко А. В., Бабич П. Н. Статистические методы в медико-биологических исследованиях с использованием Excel. Київ: Морион, 2001. 408 с.

URL: <https://www.twirpx.com/file/1466887/>

6. Мірчук Б. М., Максимов Я. В. Застосування тимчасових дентальних імплантатів в якості скелетної опори при ортодонтичному лікуванні вторинних деформацій у пацієнтів з дефектами зубних рядів у бічних ділянках. *East European Scientific Journal*. 2019. No. 9 (49), part 2. P. 19-25.

URL: https://eesa-journal.com/wp-content/uploads/EESA_september_part_2.pdf

7. Мірчук Б. М., Максимов Я. В. Частота дефектів зубних рядів серед дорослих пацієнтів м. Запоріжжя, які звернулися за протетичним лікуванням. *Актуальні питання фармацевтичної і медичної науки*

та практики. 2017. Т. 10, № 1. С. 102-106. DOI: <https://doi.org/10.14739/2409-2932.2017.1.93452>

8. Пехньо В. В. Поширеність дефектів зубних рядів у вагітних. *Вісник проблем біології і медицини*. 2016. Вип. 4. Т. 2, № 134. С. 270-272. URL: <https://cyberleninka.ru/article/n/poshirenist-defektiv-zubnih-ryadiv-u-vagitnih/viewer>

9. Плас Дж. В. Python для сложных задач. *Наука о данных и машинное обучение*. Санкт-Петербург: Питер, 2018. 576 с.

URL: <https://habr.com/ru/company/piter/blog/339766/>

10. Реброва О. Ю. Статистический анализ медицинских данных. Применение пакета прикладных программ STATISTICA. Москва: МедиаСфера, 2002. 312 с. URL: <https://www.twirpx.com/file/1440496/>

11. Рівіс О. Ю. Апаратурно-хірургічне лікування зубощелепних аномалій та деформацій з використанням скелетної опори на мініімплантати (експериментально-клінічне дослідження): автореф. дис. ... канд. мед. наук: 14.01.22 / Ужгород. нац. ун-т. Ужгород, 2017. 20 с.

12. Спосіб визначення мезіодистальних розмірів втрачених зубів у пацієнтів з дефектами зубних рядів: пат. на корисну модель Україна. № 119712; заяв. 10.10.2017.

13. Deepak Nallaswamy. Textbook of Prosthodontics. JP: Medical Ltd, 2017. Sept. (Vol. 30):1550. URL: <https://books.google.com.ua/books?id=DLpEDwAAQBAJ&printsec=frontcover&hl=ru#v=onepage&q&f=false>

14. Nikhil Marwah. Textbook of Pediatric Dentistry. New Delhi, London, Panama: Jaypee Brothers Medical Publishers Ltd, 2017. 1120 p.

The article was received
2020.02.12

