

**T.V. Kirieieva,  
T.A. Pertseva,  
N.K. Kravchenko,  
B.O. Basina**

## **GENETIC TESTING FOR THROMBOPHILIA IN CASE OF UNPROVOKED EPISODE OF PULMONARY EMBOLISM**

*Dnipro State Medical University  
department of internal medicine 1  
V. Vernadsky str., 9, Dnipro, 49044, Ukraine  
Дніпровський державний медичний університет  
кафедра внутрішньої медицини 1  
(зав. – д. мед. н. проф. Л.І. Конопкіна)  
вул. В. Вернадського, 9, Дніпро, 49044, Україна  
e-mail: simmetrichno@gmail.com*

**Цитування:** *Медичні перспективи. 2021. Т. 26, № 2. С. 197-201*

**Cited:** *Medicni perspektivi. 2021;26(2):197-201*

**Key words:** *pulmonary embolism, thrombophilia, low risk patient*

**Ключові слова:** *ТЕЛА, тромбофілія, пацієнт низького ризику*

**Ключевые слова:** *ТЭЛА, тромбофилия, пациент низкого риска*

**Abstract. Genetic testing for thrombophilia in case of unprovoked episode of pulmonary embolism. Kirieieva T.V., Pertseva T.A., Kravchenko N.K., Basina B.O.** *Venous thromboembolism (pulmonary embolism (PE) and deep vein thrombosis (DVT)) is the third among all cardiovascular syndromes in the world, second only to heart attack and stroke. Estimation of clinical probability of this condition takes into account many factors, including age. But in case of PE probability in young patient data of scales such as Geneva Score (Revised), Wells' criteria for pulmonary embolism, the PERC rule may be misleading. For this group a new influential factor emerges – thrombophilia. The aim of our work was to demonstrate the approach to identifying whom and when to test for genetic predisposition for thrombosis, based on a clinical case of young male with unprovoked episode of PE. Testing patients for thrombophilia is a good way to develop a personalised approach in case of prescribing long-term anticoagulant treatment. Moreover, patient's awareness about congenital condition helps to increase compliance which is crucial, due to the fact that in case of unprovoked pulmonary embolism another episode can occur in up to 50 % of cases during the next 5 years. In addition, further accumulation and analysis of data on the amount of genetic risk factors for thrombosis will expand our understanding of this issue and in the future will allow us to better diagnose and treat this condition.*

**Реферат. Генетичне тестування на тромбофілію в разі неспровокованого епізоду ТЕЛА. Кірієєва Т.В., Перцева Т.О., Кравченко Н.К., Басіна Б.О.** *Венозні тромбоемболії (тромбоемболія легеневої артерії (ТЕЛА) і тромбоз глибоких вен (ТГВ)) в усьому світі посідають третє місце серед усіх кардіоваскулярних синдромів, поступаючи тільки інфаркту та інсульту. Оцінка клінічної ймовірності цього стану враховує безліч факторів, у тому числі вік. Однак при оцінці ймовірності ТЕЛА в молодих пацієнтів без значущих чинників ризику за допомогою основних шкал, таких як r Geneva Score (Revised), Wells 'Criteria for Pulmonary Embolism, правило PERC, отриманий результат може не відповідати клінічній картині. Для таких хворих зростає роль наявності генетичної схильності до тромбоутворення - тромбофілії. Метою нашої роботи було на прикладі клінічного випадку продемонструвати місце тестування на тромбофілію в плані ведення молодого хворого з неспровокованим епізодом ТЕЛА. Тестування пацієнтів на тромбофілію допомагає у розробці персоналізованого підходу в разі необхідності призначення тривалої терапії антикоагулянтами. Крім того, обізнаність пацієнта щодо своєї генетичної схильності допомагає підвищити комплаєнтність, що вкрай важливо з огляду на високий ризик повторних епізодів тромбозу в наступні п'ять років. Крім того, подальше накопичення і аналіз даних про сукупність генетичних факторів ризику тромбозу розширить наше розуміння цієї проблеми і в майбутньому дозволить нам краще діагностувати та лікувати цей стан.*

Venous thromboembolism (pulmonary embolism (PE) and deep vein thrombosis (DVT)) is the third among all cardiovascular syndromes in the world, second only to heart attack and stroke [9, 10]. PE is one of the most formidable complications developing in postoperative patients and patients with lower limb vascular thrombosis.

Nowadays, in clinical practice we have tools which help us to objectify the risk of PE development in order to either timely prevent or treat it. The risk of PE is determined by the Geneva Score (Revised), Wells' Criteria for Pulmonary Embolism, the PERC rule. They all take into account risk factors such as age ( $\geq 65$  years old Geneva Score and

>50 years old PERC), prolonged immobilization, surgical intervention and history of DVT [11, 6]. However, in clinical practice, cases of PE development in young patients without the so-called "strong provoking factors" are rather common. In this cases a new factor emerges – genetic predisposition known as thrombophilia. This term means an increased tendency to thrombosis developing as a result of genetic or acquired changes in the haemostatic system [8, 9].

In routine clinical practice, detection of thrombophilia is most commonly used in management of pregnancy and the postpartum period [4]. The role of genetic predisposition is also considered when planning surgical interventions so as to predict the need for the prevention of thrombosis in the post-operative period. For this, the Caprini scale is used (mutations of factor V (Leiden) and the prothrombin gene is taken into account). In case of hospitalized non-surgical patients, the need for thromboprophylaxis is determined by the PADUA score in which the presence of a previously diagnosed thrombotic condition is also considered. However, in the diagnosis and further management of patients with pulmonary embolism, the role of thrombophilia markers is not unambiguous [7].

In majority of cases, detection of this condition in patients with PE is the final stage of the diagnostic search, after all provoking factors have been excluded. Only in case of an "unprovoked" PE it makes sense to think about conducting tests for thrombophilia. Currently, there is no unequivocal approach to decide whom and when to test. For example, the British committee for standards in haematology, 2010 in its recommendations states that it is not

possible to give valid recommendations regarding testing of patients and their families [1]. Recently, a number of publications systematized the approach to this issue. Scott M. Stevens et al., 2016, based on a meta-analysis of large studies, concluded that testing for a genetic predisposition in patients with unprovoked thrombosis is not worth, except for cases when presence of thrombophilia gene can increase patient's adherence to anticoagulant therapy [3]. On the other hand all publications emphasize that this field continues to develop. Moreover, all current studies considered only factors strongly associated with the risk of thrombosis (antithrombin (AT), protein C (PC) and protein S (PS) factor V Leiden (FVL) and the prothrombin gene 20 210 A / G (PGM) mutations), while other factors currently available for determination ((PAI-1), and the 4G / 5G PAI-1 promoter polymorphism, folate cycle mutations MTHFR 677 and MTRR 66) and their combinations were not taken into account [2].

The aim of our work was to show, the role of testing for thrombophilia in young patients without "major risk factors" of PE basing on the clinical case.

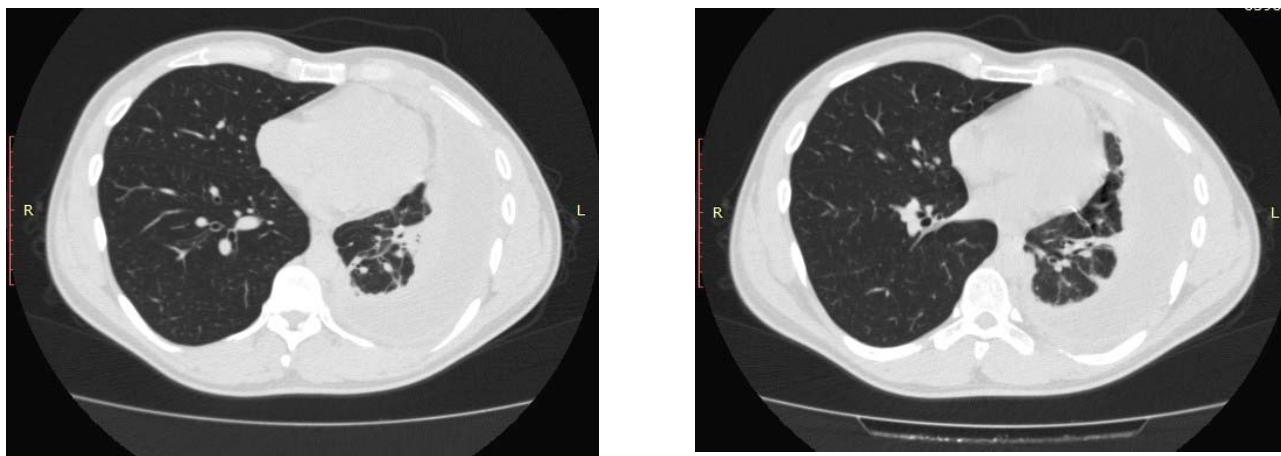
A 36-year-old male was admitted to the hospital with complains on dyspnea left sided chest pain, fever 37,7°C, SpO<sub>2</sub> 94 %. Prior to this he has been ill for 3 days, the onset was acute, initial symptoms were chest pain and fever and mild dyspnea on exertion. Chest X-ray showed left-sided pleural effusion and a diagnose of CAP was established (Fig. 1). Pleural fluid analysis showed exudate and patient was given the standard antibacterial therapy (amoxicillin+clavulanic acid 1.2 g iv t.i.d. and azythromicine 500 mg per os q.d.).

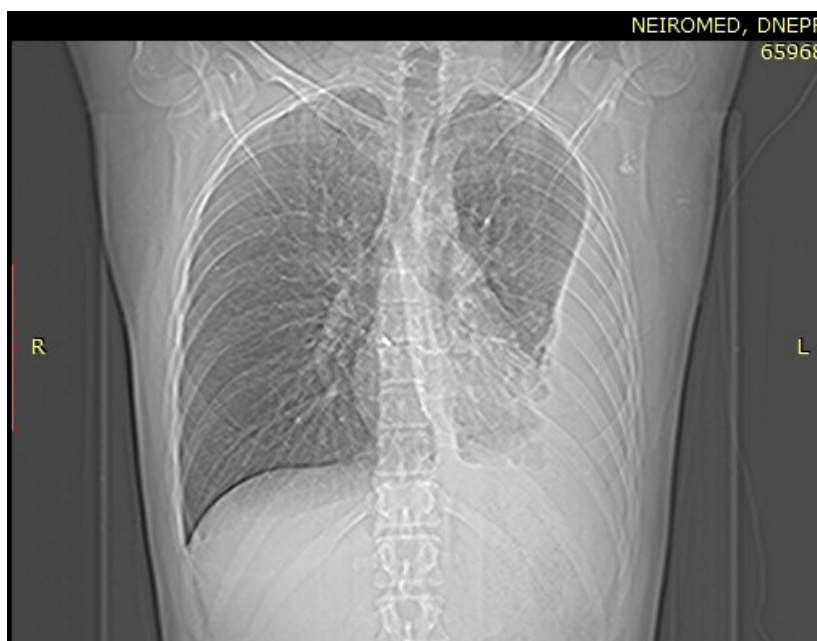

Fig. 1. Frontal chest X-ray on the day of admission

On day three he showed no clinical improvement and a CT scan of chest was performed. It showed partial atelectasis of the lower lobe of the left lung

with multiple isolated effusions in paracostal (52 mm), supraphrenic (32 mm), and interlobar (31 mm) areas (Fig. 2).

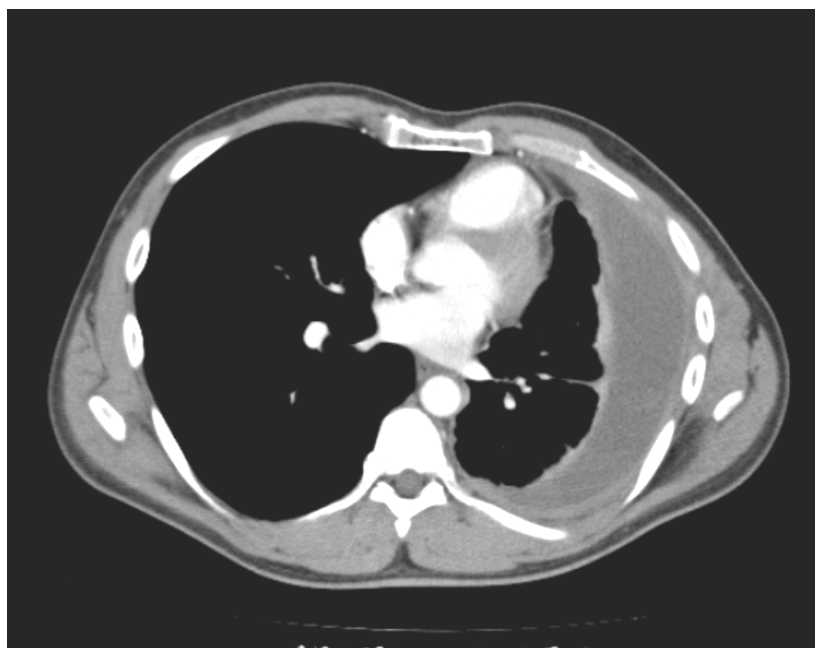


**Fig. 2.** Chest CT on day three of treatment

Due to the fact that clinical signs of the disease differed from the typical clinic of pneumonia: absence of leukocytosis, low CRP (16.8 mg/l), the absence of purulent sputum and limited pleural effusion, the diagnosis of CAP was considered as unlikely, unfortunately pneumonia is still often misdiagnosed [5]. In addition, guided by the ultrasound another thoracocentesis was performed in order to check the fluid for presence of mycobacterium and other bacterium. PCR for all

pathogens were negative. In a detailed medical history, patient mentioned that a few days before the onset of the disease, he was on a business trip and spent more than three hours on the road. This fact, in combination with the clinical picture atypical for pneumonia, made it possible to suspect PE.

First of all we considered a pre-test probability of this diagnosis. Judging by Wells scale the probability of PE was 0 points, rGeneva – 3 points (due to tachycardia), PERC rule – 0 points.



**Fig. 3.** CT pulmonary angiography

However, a decision was made to determine the level of D-dimer, which significantly exceeded normal values (4781 FEO/ml). A computed tomographic pulmonary angiography was performed (Fig. 3). It revealed left-sided pulmonary embolism with parietal thrombi of subsegmental arteries of the lower lobe of the left lung and pulmonary infarctions in S 5, 6, 9 of the left lung. Thus a diagnosis of PE was confirmed. Ultrasonography found no signs of DVT of lower limbs.

Patient was prescribed 30 mg of rivaroxaban per day with positive clinical effect. Provided that this episode of PE was recognised as unprovoked the patient was tested for thrombophilia. The following mutations were detected: heterozygous carriage of folate cycle mutations (MTRR 66, MTHFR1298, MTHFR 677, MTR 2756), factor XIII F13A1 mutation (heterozygous carriage), platelet glycoprotein 1β GP1BA gene (heterozygous carriage 1), PAI-1 (heterozygous carriage 1). Markers of antiphospholipid syndrome have not been found. Given that the patient was on anticoagulant therapy, activity of antithrombin and levels of proteins C and S were not determined.

Despite the fact that all of the detected mutations themselves are not considered to increase the risk of

venous thrombosis, it is likely that their combination has a similar effect.

## CONCLUSIONS

1. Nowadays, the health status of the young able to work population is often poor due to increasing prevalence of obesity, smoking and sedentary lifestyle, which makes them prone to developing PE. Thus, testing for thrombophilia in young patients with unprovoked PE is reasonable and feasible approach.

2. On the one hand, this is a way to inform the patient about the real risk of a repeated episode of thrombosis, which in the case of unprovoked pulmonary embolism occurs in 50% during the next 5 years, and thus to improve compliance when developing a thromboprophylaxis strategy. On the other hand, further accumulation and analysis of data on the totality of genetic risk factors for thrombosis will expand our understanding of this issue and in the future will allow us to better diagnose and treat this condition.

Conflict of interests. The authors declare no conflict of interest.

## REFERENCES

1. Baglin T, Gray E, Greaves M, Hunt BJ, Keeling D, Machin S, Mackie I, Makris M, Nokes T, Perry D, Tait RC, Walker I, Watson H; British Committee for Standards in Haematology. Clinical guidelines for testing for heritable thrombophilia. *Br J Haematol.* 2010 Apr;149(2):209-20. Epub 2010 Jan 28. PMID: 20128794. doi: <https://doi.org/10.1111/j.1365-2141.2009.08022.x>
2. Connors JM. Thrombophilia Testing and Venous Thrombosis. *N Engl J Med.* 2017 Sep 21;377(12):1177-1187. PMID: 28930509. doi: <https://doi.org/10.1056/NEJMra1700365>
3. Stevens SM, Woller SC, Bauer KA, Kasthuri R, Cushman M, Streiff M, Lim W, Douketis JD. Guidance for the evaluation and treatment of hereditary and acquired thrombophilia. *J Thromb Thrombolysis.* 2016 Jan;41(1):154-64. PMID: 26780744; PMCID: PMC4715840. doi: <https://doi.org/10.1007/s11239-015-1316-1>
4. Bates SM, Middeldorp S, Rodger M, James AH, Greer I. Guidance for the treatment and prevention of obstetric-associated venous thromboembolism. *J Thromb Thrombolysis.* 2016 Jan;41(1):92-128. PMID: 26780741; PMCID: PMC4715853. doi: <https://doi.org/10.1007/s11239-015-1309-0>
5. Kireyeva TV., Basina BO., Kravchenko NK. Pneumonia misdiagnosis. Are we losing time? // *The Pharma Innovation Journal.* 2019; 8(5): 92-94
6. Maynard G, Jenkins IH, Merli GJ. Venous thromboembolism prevention guidelines for medical inpatients: mind the (implementation) gap. *J Hosp Med.* 2013 Oct;8(10):582-8. Epub 2013 Aug 27. PMID: 23983041. doi: <https://doi.org/10.1002/jhm.2071>
7. Middeldorp S. Inherited thrombophilia: a double-edged sword. *Hematology Am Soc Hematol Educ Program.* 2016 Dec 2;2016(1):1-9. PMID: 27913455; PMCID: PMC6142488. doi: <https://doi.org/10.1182/asheducation-2016.1.1>
8. Momot A.P. The problem of thrombophilia in clinical practice. *Journal of Pediatric Hematology and Oncology.* 2015;2(1):36-48. Russian. doi: <https://doi.org/10.17650/2311-1267-2015-1-36-48>
9. Rana S. Acute pulmonary embolism in young: Case reports. *J Assoc Chest Physicians* 2017;5:46-50. doi: <https://doi.org/10.4103/2320-8775.196657>
10. Raskob GE, Angchaisuksiri P, Blanco AN, Buller H, Gallus A, Hunt BJ, Hylek EM, Kakkar A, Konstantinides SV, McCumber M, Ozaki Y, Wendelboe A, Weitz JI; ISTH Steering Committee for World Thrombosis Day. Thrombosis: a major contributor to global disease burden. *Arterioscler Thromb Vasc Biol.* 2014 Nov;34(11):2363-71. PMID: 25304324. doi: <https://doi.org/10.1161/ATVBAHA.114.304488>
11. Konstantinides SV, Meyer G, Becattini C, Bueno H, Geersing GJ, Harjola VP, Huisman MV, Humbert M, Jennings CS, Jiménez D, Kucher N, Lang IM, Lankeit M, Lorusso R, Mazzolai L, Meneveau N, Ainle FN, Prandoni P, Pruszczyk P, Righini M, Torbicki A, Van Belle E, Zamorano JL. The Task Force for the diagnosis and management of acute pulmonary embolism of the

European Society of Cardiology (ESC). 2019 ESC Guidelines for the diagnosis and management of acute pulmonary embolism developed in collaboration with the European Respiratory Society (ERS): The Task Force for

the diagnosis and management of acute pulmonary embolism of the European Society of Cardiology (ESC). *Eur Respir J*. 2019 Oct 9;54(3):1901647. PMID: 31473594. doi: <https://doi.org/10.1183/13993003.01647-2019>

## СПИСОК ЛІТЕРАТУРИ

1. Clinical guidelines for testing for heritable thrombophilia / T. Baglin et al. *Br. Journal of Haematology*. 2010. P. 209-220. Epub 2010 Jan 28. PMID: 20128794.

DOI: <https://doi.org/10.1111/j.1365-2141.2009.08022.x>

2. Connors J. M. Thrombophilia Testing and Venous Thrombosis. *N Engl J Med*. 2017. 21. Sep. (Vol. 377, No. 12). P. 1177-1187. PMID: 28930509. DOI: <https://doi.org/10.1056/NEJMra1700365>

3. Guidance for the evaluation and treatment of hereditary and acquired thrombophilia / S. M. Stevens et al. *J Thromb Thrombolysis*. 2016. Vol. 41, No. 1. P. 154-164. PMID: 26780744; PMCID: PMC4715840.

DOI: <https://doi.org/10.1007/s11239-015-1316-1>

4. Guidance for the treatment and prevention of obstetric-associated venous thromboembolism / S. M. Bates et al. *J Thromb Thrombolysis*. 2016. Vol. 41, No. 1. P. 92-128. PMID: 26780741; PMCID: PMC4715853. DOI: <https://doi.org/10.1007/s11239-015-1309-0>

5. Kireyeva T. V., Basina B. O., Kravchenko N. K. Pneumonia misdiagnosis. Are we losing time? *The Pharma Innovation Journal*. 2019. Vol. 8, No. 5. P. 92-94.

6. Maynard G., Jenkins I. H., Merli G. J. VTE Prevention Guidelines for Inpatients. *J. Hosp. Med*. 2013. Vol. 10. P. 582-588. Epub. 2013 Aug 27. PMID: 23983041. DOI: <https://doi.org/10.1002/jhm.2071>

7. Middeldorp S. Inherited thrombophilia: a double-edged sword. *Hematology Am Soc Hematol Educ Program*. 2016. P. 1-9. PMID: 27913455; PMCID: PMC6142488. DOI: <https://doi.org/10.1182/asheducation-2016.1.1>

8. Momot A. The problem of thrombophilia in clinical practice. *Rus. Journal of Children Hematology and Oncology*. 2015. Vol. 2. P. 36-48. DOI: <https://doi.org/10.17650/2311-1267-2015-1-36-48>

9. Rana S. Acute pulmonary embolism in young: Case reports. *J Assoc Chest Physicians*. 2017. Vol. 5. P. 46-50. DOI: <https://doi.org/10.4103/2320-8775.196657>

10. Thrombosis: a major contributor to global disease burden / G. E. Raskob et al. *Arterioscler Thromb Vasc Biol*. 2014. P. 2363-71. PMID: 25304324. DOI: <https://doi.org/10.1161/ATVBAHA.114.304488>

11. 2019 ESC Guidelines for the diagnosis and management of acute pulmonary embolism developed in collaboration with the European Respiratory Society (ERS): The Task Force for the diagnosis and management of acute pulmonary embolism of the European Society of Cardiology (ESC) / Stavros V. Konstantinides et al. *European Heart Journal*. 2020. Vol. 41. P. 543-603. PMID: 31473594.

DOI: <https://doi.org/10.1183/13993003.01647-2019>

Стаття надійшла до редакції  
09.12.2020

