

& *Reconstruction Open*. 2017. Vol. 1. P. 9-14.
DOI: <https://doi.org/10.1055/s-0037-1603578>

14. The use of microplates for fixation of mandibular fractures: a systematic review / M. M. Zaky et al. *J Med Sci Res*. 2019. Vol. 2. P. 1-7.

DOI: https://doi.org/10.4103/JMISR.JMISR_9_19

15. Van der Kolk – Bender C. A, Koudstaal M. J., Wolvius E. B. Treatment of Severely Atrophic Edentulous Mandible Fractures: Load-Bearing or Load-Sharing? *Craniofacial Trauma Reconstruction Open*. 2018. Vol. 2. P. 55-60.

DOI: <https://doi.org/10.1055/s-0038-1667295>

The article was received
2020.09.12



UDC 616.31:616.314-77]-056.83(043.3)

<https://doi.org/10.26641/2307-0404.2021.1.228019>

**A.I. Foros,
Ye.Ya. Kostenko,
M.Yu. Goncharuk-Khomyn**

ASSESSMENT OF THE DENTAL STATUS OF DRUG-ADDICTED PATIENTS WITH PARAFUNCTION OF THE DENTAL-JAW APPARATUS

HEI «Uzhhorod National University»
Faculty of Dentistry
Department of Orthopedic Dentistry
University str., 16, Uzhhorod, 88000, Ukraine
ДВНЗ «Ужгородський національний університет»
стоматологічний факультет
кафедра ортопедичної стоматології
(зав. – к. мед. н., доц. С.Б. Костенко)
вул. Університетська, 16, Ужгород, 88000, Україна
e-mail: anat.foros@gmail.com

Цитування: *Медичні перспективи*. 2021. Т. 26, № 1. С. 217-225

Cited: *Medicni perspektivi*. 2021;26(1):217-225

Key words: *parafunctions, drug addiction, bruxism, dentin, enamel*

Ключові слова: *парафункції, наркозалежність, бруксизм, дентин, емаль*

Ключевые слова: *парафункции, наркозависимость, бруксизм, дентин, эмаль*

Abstract. Assessment of the dental status of drug-addicted patients with parafunction of the dental-jaw apparatus. Foros A.I., Kostenko Ye.Ya., Goncharuk-Khomyn M.Yu. The number of drug addicts in the world is growing every year. The aim of the study was to assess the dental status of drug-addicted patients with parafunction of the dental-jaw apparatus. We used clinical, analytical, functional and histological research methods. 119 drug-addicted and 110 non-drug-dependent patients aged 18 to 54 were examined. In order to confirm the presence of parafunctions of the dental-jaw apparatus in patients, we conducted an occludogram study, as well as an assessment of the index of

parafunctions of the masticatory muscles and the degree of their severity. The structure of tooth tissues was examined by histological method. Examination of drug-addicted patients revealed the presence of numerous carious cavities, secondary adentia, enamel erosion, pathological abrasion, signs of gingivitis and periodontitis, tooth chipping. The prevalence of parafunction of the dental-jaw apparatus, in particular bruxism, in drug-addicted patients is 1.56 times higher than this figure among non-drug addicts. The results of the occlusogram and the index of parafunctions of the masticatory muscles differ significantly between the study groups. The mean value of the masticatory muscle parafunction index among drug-addicted patients is 2.06 times significantly higher than the value among non-drug-addicted men and 2.03 times higher among women. Histological examination of the tooth tissues of drug-addicted patients indicates a disorder of the mineralization of both enamel and dentin. Thinning of the peripheral zone of the pulp, which is normally represented by a layer of odontoblasts, which provide regeneration and nutrition of dentin, is more common in persons under 25 years of age. Drug use adversely affects the dental status of patients and the condition of the hard tissues of the tooth.

Реферат. Оцінка стоматологічного статусу наркозалежних пацієнтів з парафункціями зубо-щелепового апарату. Форос А.І., Костенко Є.Я., Гончарук-Хомин М.Ю. *Кількість наркозалежних у світі зростає з кожним роком. Метою дослідження було провести оцінку стоматологічного статусу наркозалежних пацієнтів з парафункціями зубо-щелепового апарату. Нами використано клінічні, аналітичні, функціональні та гістологічні методи дослідження. Проведено огляд 119 наркозалежних та 110 ненаркозалежних пацієнтів віком від 18 до 54 років. З метою підтвердження наявності в пацієнтів парафункцій зубо-щелепового апарату нами проведено дослідження оклюдограми, а також проведено оцінку індексу парафункції жувальних м'язів й установлення ступеня їх тяжкості. Гістологічним методом досліджено будову тканин зуба. Під час проведення огляду наркозалежних пацієнтів було виявлено наявність численних каріозних порожнин, вторинної адентії, ерозії емалі, патологічної стертості, ознаки гінгівіту та пародонтиту, сколи зубів. Поширеність парафункцій зубо-щелепового апарату, зокрема бруксизму, у наркозалежних пацієнтів в 1,56 раза перевищує цей показник серед ненаркозалежних. Отримані результати оклюдограми та індексу парафункції жувальних м'язів суттєво відрізняються між досліджуваними групами. Середнє значення індексу парафункції жувальних м'язів серед наркозалежних пацієнтів у 2,06 раза достовірно перевищує значення серед ненаркозалежних чоловіків та в 2,03 раза серед жінок. Гістологічне дослідження тканин зуба наркозалежних пацієнтів свідчить про порушення мінералізації як емалі, так і дентину. В осіб віком до 25 років частіше виявляється стоншення периферійної зони пульпи, яка в нормі представлена шаром одонтобластів, що забезпечують регенерацію та живлення дентину. Вживання наркотичних речовин негативно впливає на стоматологічний статус пацієнтів та стан твердих тканин зуба.*

The number of drug addicts in the world is growing every year [3, 6]. Drugs adversely affect the human body, including the condition of the oral cavity and hard tissues of the teeth [2, 5]. This in turn leads to the development of parafunctions of the dental-jaw apparatus, in particular to bruxism. The connection between the occurrence and nature of oral diseases with drug use today is not in doubt [4, 6]. Correction of the method of treatment depending on the progression of pathology or specific changes that occur in the process of specialized treatment will ensure the implementation of the most complete and predictable treatment algorithm for patients of this profile. The literature describes the most characteristic disorders of the dental-jaw apparatus, which occur in the process of drug dependence on cocaine [8, 11, 12], cannaboids, opiates, hallucinogens, heroin and methadone, which plays an important role in the possibility of suspicion of drug addiction of patients during dental treatment [9, 10].

The combination of permanent prosthetics with the use of orthodontic appliances, splints, splendors and deprogrammers will stabilize the existing changes in the dental status of drug-addicted patients

with parafunctions, this will help to implement a comprehensive algorithm for rehabilitation of drug users. Taking into account the peculiarities of the manifestations of parafunctions in drug addicts and patients of drug treatment facilities play an important role in choosing an adequate method of treatment.

Thus, the purpose of the research is to assess the dental status of drug-addicted patients with parafunction of the dental-jaw apparatus.

MATERIALS AND METHODS OF RESEARCH

We used clinical, analytical, functional and histological research methods [1, 7, 14]. 119 patients of the communal non-profit enterprise "Transcarpathian Regional Medical Center for Mental Health and Addiction Medicine" of the Transcarpathian Regional Council in Uzhhorod were examined with their prior consent and with observance of data anonymity (main group). Patients, in the anamnesis of which there are no data on drug use (110 patients), with their consent were selected to the study group (comparison group). Age of patients was from 18 to 54 years.

Clinical and instrumental examination of patients was performed according to the generally accepted algorithm of the World Health Organization. According to the Commission on Biomedical Ethics (Protocol N 5 of 10.03.2020), the experimental studies were carried out in compliance with the basic provisions of the GCP (1996), the Council of Europe Convention on Human Rights and Biomedicine (1997), the Helsinki Declaration of the World Medical Association on Ethical Principles conducting scientific and medical research with human participation (1964–2000) and Order N 66 of the Ministry of Health of Ukraine of February 13, 2006.

In order to confirm the presence of parafunctions of the dental-jaw apparatus in our patients, we conducted an occlusogram study, as well as an assessment of the index of parafunctions of the masticatory muscles and the degree of their severity according to the methods described by Flejsher G. [7].

In order to assess the presence of occlusal contacts, occlusograms were used, with their imaging on a wax plate. After conducting this study, it was found that 100% of subjects have supercontacts on the occlusal surfaces of premolar and molar of both jaws. To determine the occlusal contacts, a double-sided two-color articulation paper from Bausch with a thickness of 40 μm was used. Occlusal contacts were determined on both jaws [7]. With the mouth wide open, a piece of paper was placed on the lower jaw and the patient was asked to forcefully close the mouth several times until the teeth were in full contact. At the same time on one jaw occlusal contacts were represented in blue, on the opposite – in red. Intraoral photography of the upper and lower jaws was performed. The percentage of occlusal contacts of the teeth was calculated using the «Stepanizer» and «ImageJ» programs.

Mathematical analysis of data and verification of the results, in particular the calculation of arithmetic mean and standard errors were performed on the basis of software "Statistica 6.0" and "Microsoft Excel 2010". Statistical analysis of the results was performed using standard statistical programs "Statistica 6.0" and "SPSS 14" (Stat Soft Inc.). Statistical data processing was performed by methods of variation statistics with the calculation of arithmetic mean values (M), standard deviation (t), standard error of the mean (m). As well as the share of the studied feature in the general population (P), standard deviation (t), standard error of the mean (m). Student's t-test for independents was used variables. The critical level of statistical significance of the null hypothesis was taken at $p < 0.05$ [1].

The study compared the clinical status with the data of histological examination of the hard tissues of the teeth.

According to the indications, in some patients 14 teeth were extracted (10 in drug addicts and 4 in non-drug addicts). Vital teeth (5 premolar and 9 molar) were extracted due to periodontal disease and grade 3 mobility. Subsequent fixation was performed in 10% formalin solution, and decalcification – in trichloroacetic acid solution. The sections were performed using a diamond burr up to 20 μm thick, after which the study of hard tissue changes was performed in direct and reflected light. The sections were stained with hematoxylin and eosin according to conventional methods [14].

RESULTS AND DISCUSSION

Among 119 examined patients with anamnestic data on drug use, 98 people (main group) showed signs of parafunction of the dental-jaw apparatus, such as pathological abrasion of the teeth, which makes up 82.35% of all examined. Among the 110 examined non-drug-dependent patients, signs of parafunction of the dental-jaw apparatus were found in 58 patients (comparison group), which is 52.73%. Thus, the prevalence of bruxism in drug-addicted patients is 1.56 times higher than in the comparison group.

The highest number of drug addicts with bruxism was observed among patients with a history of use of various drugs. This group comprises 38.78% (38 people). Patients who used or use morphine derivatives make up 25.51% (25 people) and amphetamine or cocaine – 22.45% (22 people). The smallest number – patients with anamnestic data on use of cannabis, LAD (Lysergic acid diethylamide) or marijuana and their proportion is 13.26% (13 people).

The distribution of patients with bruxism by gender and age was also carried out. Men significantly predominate in the main group (83 people) and make up by 69.4% more than the number of women (15 people). However, this is due to the predominance of men among drug addicts in general. In the comparison group, the number of women (30 people) exceeds the number of men (28 people) by 3.4%. In the main group, both in men and women, the largest number of patients with bruxism is observed at the age of 25-34 years, that is 42.2% (35 men) and 40.0% (6 women), respectively. In the comparison group, both in men and women, the largest number of patients with bruxism is observed at the age of 35-44 years, that high is 42.9% (12 men) and 36.7% (11 women), respectively. These results indicate that drugs affect the structure of tooth tissues, as "rejuvenation" of this pathological process occurs.

Examination of drug-addicted patients revealed the presence of numerous carious cavities, secondary adentia, enamel erosion, pathological abrasion, signs of gingivitis and periodontitis, tooth chipping.

We conducted an occludogram study, according to which all patients in the main and the comparison group had values less than 100%. This is regarded as an uneven distribution on the elements of the masticatory apparatus, the presence of supracontacts (Table 1). Occludogram indices are worse in women than in men in both groups. In main group the value of 50-60% dominates, which is 46.99% among men and 46.67% among women. This is 1.64 and 1.56 times higher than this index in non-drug-addicted patients. The value of the occludogram of 60-70% is observed in 34.94% of men and 40.0% women. 70-80% occur in 15.66% of drug-addicted male patients and 13.33% of women.

In the comparison group value of 60-70%, dominates which is 39.29% among men and 46.67% among women. The value of the occludogram of 50-60% is observed in 28.57% of men and 30.0% of women. 70-80% occur in 21.43% of men-drug addicts and in 6.66% of women.

Thus, the results of the occludogram differ significantly between the study groups, which confirms the negative impact of drugs on the dental status of patients.

The mean value of the masticatory muscle parafunction index for drug-addicted men is 12.03±0.64, and for women is 12.58±0.71 (Table 2). Both in males and females severe masticatory muscle parafunctions dominate, accounting for 48.19% of surveyed males drug addicts and 53.34% of females. In second place in terms of the share of parafunction of the masticatory muscles of the middle degree, the share of which is 40.97% and 33.33%, respectively. The smallest proportion falls on parafunctions of masticatory muscles of mild degree, namely 10.84 and 13.33%. The parafunction index of masticatory muscles is slightly worse in women. There was no significant difference by sex between the indices of masticatory muscles parafunction in patients of the main group (p>0.05). The mean value of the masticatory muscle parafunction index for non-drug-dependent men is 5.83±0.23, and for women is 6.17±0.41, which is significantly (p <0.05) different from the value in the main group.

Table 1

Occludogram of patients of the main and comparison group,% (P±m)

Indicator,%	Main group (98 patients)				Comparison group (58 patients)			
	Men (n=83)		Women (n=15)		Men (n=28)		Women (n=30)	
	abs.	%, P±m	abs.	%, P±m	abs.	%, P±m	abs.	%, P±m
50-60	39	46.99±0.01	7	46.67±0.01	8	28.57±0.01*	9	30.0±0.01*
60-70	29	34.94±0.01	6	40.00±0.01	11	39.29±0.01*	14	46.67±0.01*
70-80	13	15.66±0.008	2	13.33±0.003	6	21.43±0.009*	5	16.67±0.011*
80-90	2	2.41±0.01	0	0	3	10.71±0.01*	2	6.66±0.01*

Notes. * – values differ statistically significantly from the main group (p<0,05).

Histological examination of tooth tissues of drug-addicted patients showed thinning of the enamel, Hunter-Schreger bands are less pronounced, the wrong radial direction, lines of Retzius are not traced everywhere. Enamel contains low-mineralized areas, namely enamel spindles, plates and bundles. Enamel spindles are areas of enamel where the processes of odontoblasts penetrate, forming a thickening. Enamel bundles are located on the border of the transition of enamel to dentin, enamel

plates penetrate the entire thickness of the enamel. All of them indicate a disorder of mineralization and are a substrate for the occurrence of carious changes in the tooth. Areas of disturbed mineralization are also observed at the boundary of dentin and cementum (Fig. 1, 2). In some areas dentin is exposed, this creates the conditions for various chemicals to enter the dentinal tubule. Dentine tubules are clearly visible but there are areas with loss of direction.



Table 2

Index of parafunctions of masticatory muscles of patients of the main group (M±m)

Parameter	Main group (98 patients)						
	men (n=83)			women (n=15)			total,%
	abs.	%, P±m	mean value of index, M±m	abs.	%, P±m	mean value of index, M±m	
No parafunction	0	0	-	0	0	-	0
Parafunction of masticatory muscles of mild degree	9	10.84±0.009	3.43±0.13	2	13.33±0.003	3.86±0.42	11.22
Parafunction of masticatory muscles of moderate degree	34	40.97±0.01	8.14±0.6	5	33.33±0.003	8.47±0.65	39.8
Parafunction of masticatory muscles of severe degree	40	48.19±0.01	17.27±0.74	8	53.34±0.01	18.06±0.58	48.98
Average value		12.03±0.64			12.58±0.71		
The average value of masticatory muscles parafunction index of patients in the comparison group							
Average value		5.83±0.23*			6.17±0.41*		

Note. * – values that are statistically significantly different from the main group (p<0.05).

There are single areas of dead pathways and sclerosed dentin, which are formed as a result of odontoblast death and remain empty (dead pathways) or filled with a matrix (sclerosed dentin) (Fig. 3, 4). The existing spaces of the interglobular dentin of the crown and the granular layer of Thoms, which located on the border of the mantle and peripulpar dentin and are little or non-mineralized areas and are regarded as a substrate for caries. The contour lines of Owen in dentin were noted in persons under 25 years of age, which indicate periods of impaired mineralization of this tissue. Also in this age group of patients thinning of the peripheral zone of the pulp is more often found, which is normally represented by a layer of odontoblasts, the processes of which are located in the dentinal tubules. These cells are responsible for the regeneration and nutrition of dentin. No changes were detected in the cement. In the periodontium, the perforating fibers (Sharpey's fibers) are thinned, which may explain the increased mobility of some teeth in the examined drug-addicted patients.

Among the surveyed drug addicts Bojchenko O.M. et al. most often observed periodontal disease, unsatisfactory state of oral hygiene, and rapid progression of pathological changes in the periodontium in persons who regularly took narcotics. The predominance of ulcerative-necrotic

changes in people who used hypnotics was revealed. The dental status of these patients requires an individual approach to oral hygiene, treatment of pathological processes and their prevention. Treatment tactics should be differentiated, tailored to the specific patient and the characteristics of the drug that provoked this process, taking into account the duration of use, the presence or absence of concomitant pathology [2].

Klima M. et al. noted the importance of the study of hard dental tissues for postmortem toxicological examination of persons suspected of drug addiction [13]. In the study of endodontically treated teeth, the concentration of narcotic substances was higher in the crown than in the root of the tooth, which is apparently due to the absence of the vascular network as the system of drug transport in the structure of such elements.

Bahdila D. et al. confirmed the connection between periodontal disease and dental caries with cocaine use [11]. The chances of periodontitis were highest among cocaine users who used ≥3 of other substances. In addition, cigarette smoking increased the likelihood of severe periodontitis and dental caries among cocaine users, whereas those who used both cocaine and methamphetamine showed only an increase in the amount of tooth decay.

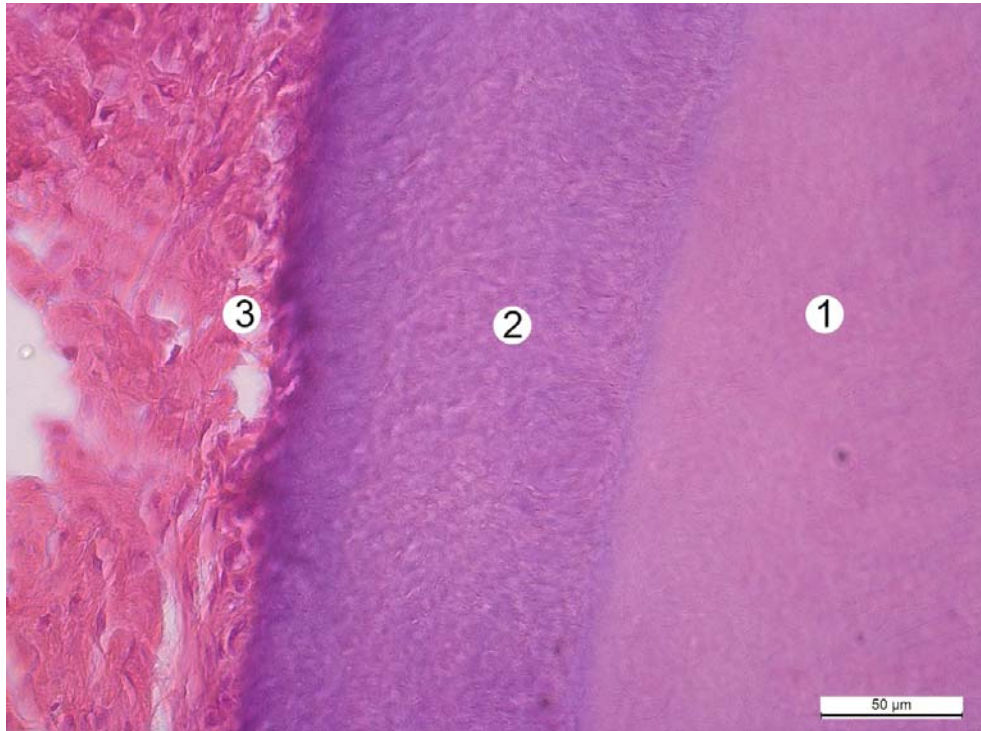


Fig. 1. Fragment of tooth root of a non-drug-addicted patient O., 37 years old. Tooth section. Staining with hematoxylin and eosin. Magnif: obj.×40, ocul.×10. Designation: 1 – mantle dentin; 2 – cement; 3 – periodontium

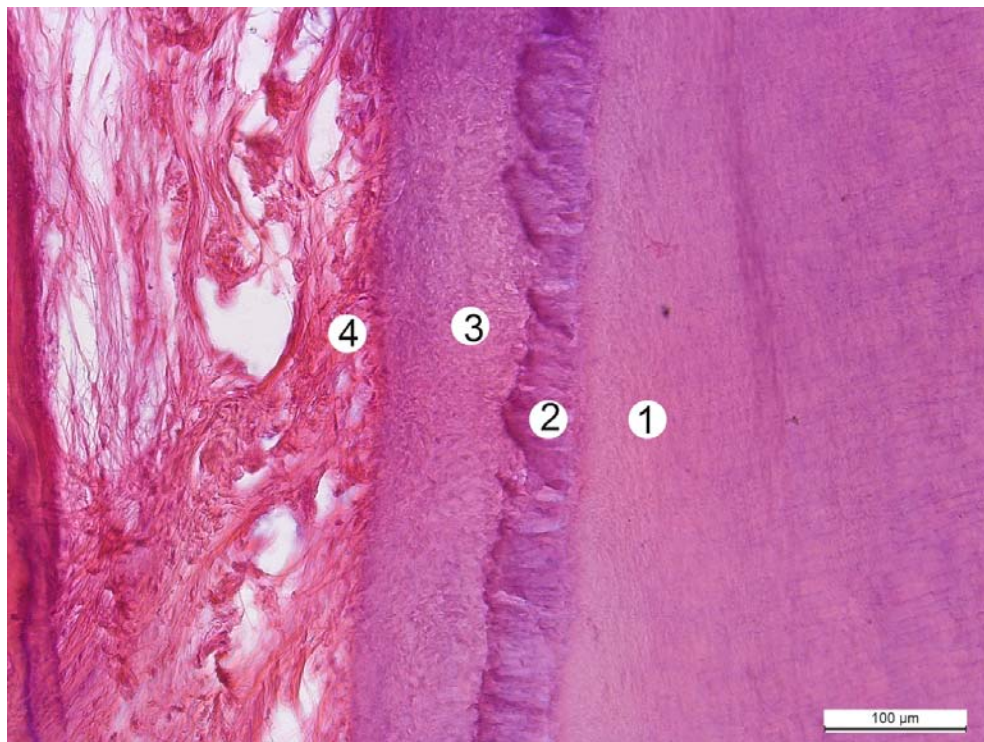


Fig. 2. Fragment of tooth root of a drug-addicted patient I., 26 years old. Tooth section. Staining with hematoxylin and eosin. Magnif: obj.×20, ocul.×10. Designation: 1 – cloak dentin; 2 – area of disturbed mineralization; 3 – cement; 4 – periodontium

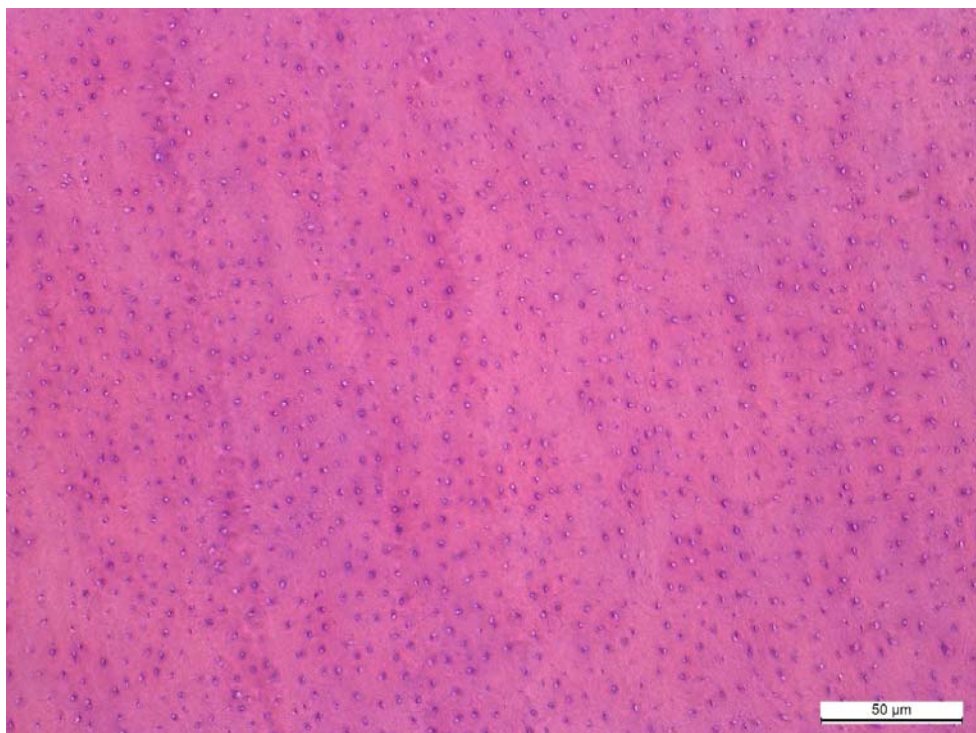


Fig. 3. Cross section of dentinal tubules of tooth of a non-drug-addicted patient V., 39 years old. Tooth section. Staining with hematoxylin and eosin. Magnif: obj.×40, ocul.×10

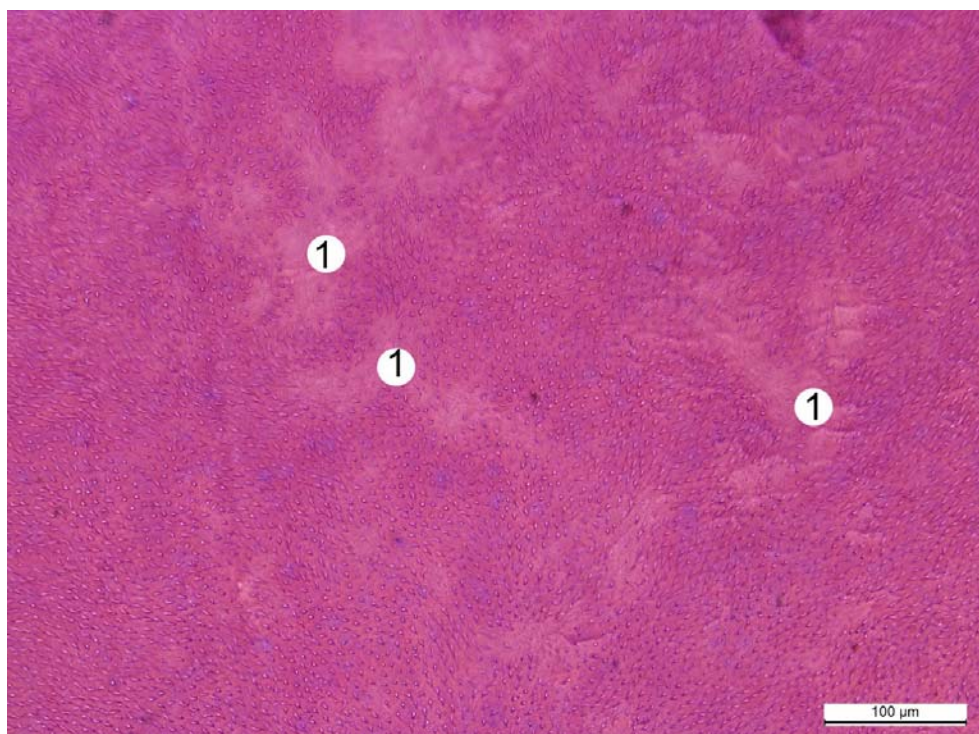


Fig. 4. Cross section of dentinal tubules of tooth of a drug-addicted patient Ye., 25 years old. Tooth section. Staining with hematoxylin and eosin. Magnif: obj.×20, ocul.×10. Designation: 1 – areas of sclerosed dentin at the sites of filling of empty dentinal tubes with dentin, which is associated with the death of odontoblasts

As a result of the examination of drug addicts, Evstratenko V.V. et al. concluded that in patients taking heroin and methadone a deterioration in dental status is noted [5]. The main manifestations of drugs are the development of carious process, inflammatory diseases of the oral cavity, salivation disorders, the formation and spread of chronic odontogenic infection. The negative effect of methadone is more pronounced in comparison with heroin due to the contact of the tablet form of the drug with the oral mucosa.

Control over changes in the structure of the dental-jaw apparatus will allow timely correction of orthopedic prosthetics in the context of systemic therapy of drug addicts in order to improve their quality of life and achieve the most effective and predictable indicators of rehabilitation.

CONCLUSIONS

1. Drug use negatively affects the dental status of patients. The prevalence of parafunction of the dental-jaw apparatus, in particular bruxism, in drug-addicted patients is 1.56 times higher than this figure among non-drug addicts.

2. The results of the occlusogram and the index of parafunctions of the masticatory muscles differ significantly between the study groups. The mean value of the masticatory muscle parafunction index among drug-addicted patients is 2.06 times significantly higher than the value among non-drug-addicted men and 2.03 times higher among women.

3. Histological examination of the tooth tissues of drug-addicted patients indicates a disorder of the mineralization of both enamel and dentin, revealed thinning of the enamel. Thinning of the peripheral zone of the pulp, which is normally represented by a layer of odontoblasts, which provide regeneration and nutrition of dentin, is more common in persons under 25 years of age.

Conflict of interest. The authors declare no conflict of interest.

Prospects for further research are to establish the relationship between changes in the dental-maxillary apparatus caused by drug use and the parameters of the active substance and the duration of dependence.

REFERENCES

1. Antomonov MYu. [Mathematical processing and analysis of medical and biological data]. Kyiv: MYTs «Medynform». 2018. p. 579. ISBN 978-966-409-202-6. Russian.
2. Boichenko OM, Petrushanko TM, Popovych IYu. [Periodontal condition of people taking various drugs]. *Svit medytsyny ta biologii*. 2019;2(68):16-19. Ukrainian. doi: <https://doi.org/10.26724/2079-8334-2019-2-68-16-19>
3. Bugorkova IA. [The prevalence of dental diseases in drug addicted patients for the development of a program to reduce risks]. *Ukraina. Zdorovia natsii*. 2015;2(34):28-31. Russian.
4. Zubachyk VM, Fedun IR. [Biochemical parameters of oral fluid in drug-addicted patients with chronic generalized periodontitis]. *Klinichna stomatologiya*. 2017;2:9-15. Ukrainian. doi: <https://doi.org/10.11603/2311-9624.2017.2.7741>
5. Evstratenko VV, Sevbitov AV, Platonova VV, Selifanova EI, Dorofeev AE. [Features of crystallization of mixed saliva in patients using heroin and methadone]. *Klinicheskaya laboratornaya diagnostika*. 2018;63(4):223-7. Russian. doi: <http://dx.doi.org/10.18821/0869-2084-2018-63-4-223-227>
6. Sokolova II, Savielieva NM. [Features of dental care and professional communication with drug addicts]. *Klinichna stomatologiya*. 2015;2:77-82.
7. Flejsher G. [Index estimation of the high-mandibular joint pathology. A guide for doctors]. Litres. 2019. p. 260. Russian.
8. Antoniazzi RP, Zanatta FB, Rosing CK, Feldens CA. Association among periodontitis and the use of crack cocaine and other illicit drugs. *J Periodontol*. 2016;87:1396-405. doi: <http://dx.doi.org/10.1902/jop.2016.150732>
9. Baghaie H, Kisely S, Forbes M, Sawyer E, Sis-kind, DJ. A systematic review and meta-analysis of the association between poor oral health and substance abuse. *Addiction*. 2017;112:765-79. doi: <http://dx.doi.org/10.1111/add.13754>
10. Bush MMA. An oral cavity profile in illicit – Drug abusers? *J Indian Soc Periodontol*. 2019;23(6):517-24. doi: http://dx.doi.org/10.4103/jisp.jisp_716_18
11. Bahdila D, Aldosari M, Abdullah A, Nelson JL, Hegazi F, Badamia R. Cocaine, polysubstance abuse, and oral health outcomes, NHANES 2009 to 2014. *Journal of Periodontology*. 2020;91(8):1039-48. doi: <http://dx.doi.org/10.1002/JPER.19-0509>
12. Cury PR, Oliveira MG, de Andrade KM, de Freitas MDS, Santos JND. Dental health status in crack/cocaine-addicted men: a cross-sectional study. *Environmental science and pollution research international*. 2017;24(8):7585-90. doi: <http://dx.doi.org/10.1007/s11356-017-8404-z>
13. Klima M, Altenburger MJ, Kempf J, Auwärter V, Neukamm MA. Determination of medicinal and illicit drugs in post mortem dental hard tissues and comparison with analytical results for body fluids and hair samples. *Forensic Science International*. 2016;265:166-71. doi: <http://dx.doi.org/10.1016/j.forsciint.2016.02.021>
14. Suvarna K, Layton C, Bancroft J. Theory and practice of histological techniques. London: Churchill Livingstone; 2018. p. 672. eBook ISBN: 9780702068874.

СПИСОК ЛІТЕРАТУРИ

1. Антомонов М. Ю. Математическая обработка и анализ медико-биологических данных. Изд. 2-е Київ: МИЦ «Мединформ». 2018. 579 с. ISBN 978-966-409-202-6
2. Бойченко О. М., Петрушанко Т. М., Попович І. Ю. Стан пародонта осіб, що приймають різні наркотичні препарати. *Світ медицини та біології*. 2019. Т. 2, № 68. С. 16-19.
DOI: <https://doi.org/10.26724/2079-8334-2019-2-68-16-19>
3. Бугоркова І. А. Распространенность стоматологических заболеваний у наркозависимых больных для разработки программы по снижению рисков. *Україна. Здоров'я нації*. 2015. Т. 2, № 34. С. 28-31.
4. Зубачик В. М., Федун І. Р. Біохімічні показники ротової рідини у наркозалежних хворих на хронічний генералізований пародонтит. *Клінічна стоматологія*. 2017. № 2. С. 9-15.
DOI: <https://doi.org/10.11603/2311-9624.2017.2.7741>
5. Особенности кристаллизации смешанной слюны у пациентов, употребляющих героин и метадон / В. В. Евстратенко и др. *Клиническая лабораторная диагностика*. 2018. Т. 63, № 4. С. 223-227.
DOI: <http://dx.doi.org/10.18821/0869-2084-2018-63-4-223-227>
6. Соколова І. І., Савельєва Н. М. Особливості надання стоматологічної допомоги та професійного спілкування з хворими на наркоманію. *Клінічна стоматологія*. 2015. № 2. С. 77-82.
7. Флейшер Г. Индексная оценка патологии высочно-нижнечелюстного сустава: руководство для врачей. *Litres*. 2019. 260 с.
8. Association among periodontitis and the use of crack cocaine and other illicit drugs / R. P. Antoniazzi et al. *J Periodontol*. 2016. Vol. 87. P. 1396-1405.
DOI: <http://dx.doi.org/10.1902/jop.2016.150732>
9. A systematic review and meta-analysis of the association between poor oral health and substance abuse / H. Baghaie et al. *Addiction*. 2017. Vol. 112. P. 765-779.
DOI: <http://dx.doi.org/10.1111/add.13754>
10. Bush M. M. A. An oral cavity profile in illicit - Drug abusers? *J Indian Soc Periodontol*. 2019. Vol. 23, No. 6. P. 517-524.
DOI: http://dx.doi.org/10.4103/jisp.jisp_716_18
11. Cocaine, polysubstance abuse, and oral health outcomes, NHANES 2009 to 2014 / D. Bahdila et al. *Journal of Periodontology*. 2020. Vol. 91, No. 8. P. 1039-1048. DOI: <http://dx.doi.org/10.1002/JPER.19-0509>
12. Dental health status in crack/cocaine-addicted men: a cross-sectional study / P. R. Cury et al. *Environmental science and pollution research international*. 2017. Vol. 24, No. 8. P. 7585-7590.
DOI: <http://dx.doi.org/10.1007/s11356-017-8404-z>
13. Determination of medicinal and illicit drugs in post mortem dental hard tissues and comparison with analytical results for body fluids and hair samples / M. Klima et al. *Forensic Science International*. 2016. Vol. 265. P. 166-171.
DOI: <http://dx.doi.org/10.1016/j.forsciint.2016.02.021>
14. Suvarna K., Layton C., Bancroft J. Theory and practice of histological techniques. London: Churchill Livingstone. 2018. 672 p. eBook ISBN: 9780702068874.

The article was received
2020.09.23

