

**M.A. Shyshkin,
T.O. Khrystenko**

COMPARATIVE ANALYSIS OF ALDEHYDE DEHYDROGENASE 1 EXPRESSION IN POLYPS AND ADENOCARCINOMA OF THE DISTAL COLON

Zaporizhzhia State Medical University
Department of Pathological Anatomy and Forensic Medicine
Maiakovskiy av., 26, Zaporizhzhia, 69035, Ukraine
Запорізький державний медичний університет
кафедра патологічної анатомії та судової медицини
(зав. – проф. С.І. Тертишний)
пр. Маяковського, 26, Запоріжжя, 69035, Україна
e-mail: khrystenko.ta@gmail.com

Цитування: *Медичні перспективи*. 2020. Т. 25, № 4. С. 94-98

Cited: *Medicni perspektivi*. 2020;25(4):94-98

Key words: polyps, colorectal cancer, aldehyde dehydrogenase 1

Ключові слова: поліпи, колоректальний рак, альдегіддегідрогеназа 1

Ключевые слова: полипы, колоректальный рак, альдегиддегидрогеназа 1

Abstract. Comparative analysis of aldehyde dehydrogenase 1 expression in polyps and adenocarcinoma of the distal colon. Shyshkin M.A., Khrystenko T.O. Aldehyde dehydrogenase 1 (ALDH1) is one of the most widely used cancer stem cells markers, even though the question of its significance for certain stages of colorectal carcinogenesis is still unclear. The aim of this study was to compare ALDH1 immunohistochemical expression levels in polyps and adenocarcinoma of the distal colon. Histopathological and immunohistochemical studies of biopsies from 40 patients (biopsies of polyps and histologically non-changed mucosa of the distal colon), as well as surgical material of colorectal adenocarcinoma from 30 patients were carried out. It was established that distal colonic polyps are characterized by cytoplasmic expression of ALDH1 with the median of relative area that is equal to 25.63 (18.26; 30.42)% stromal cells. ALDH1 expression by epitheliocytes is revealed exclusively in dysplastic polyps with the median of the area that is equal to 22.13 (17.22; 30.05)%. Colorectal adenocarcinoma is characterized by cytoplasmic expression of ALDH1 with the medians of the area that are equal to 40,22 (22,54; 47,77)% stromal cells and 32,12 (23.64; 40.28)% cancer cells. The area of ALDH1+ cells varies depending on the pTNM stage of the carcinoma, herewith the median of ALDH1+ stromal cells is significantly increasing during the tumor progression from the I to the III stages that displays increasing in number of stromal cells which are involved in oncogenic signaling pathways activation. The median of ALDH1+ cancer cells is significantly increasing during the tumor progression from the III to the IV stages that shows increasing number of cancer cells that acquire properties of stem cells on advanced stages of colorectal adenocarcinoma. Comparative analysis of the parameters obtained for polyps and carcinoma indicates that the median of ALDH1+ stromal cells area in polyps is 2 times smaller than the median of ALDH1+ stromal cells area in carcinoma, and the median of ALDH1+ epitheliocytes area in polyps is 1.5 times smaller than the median of ALDH1+ cancer cells area.

Реферат. Порівняльний аналіз експресії альдегіддегідрогенази 1 в поліпах і аденокарциномі дистальної товстої кишки. Шишкін М.А., Христенко Т.О. Альдегіддегідрогеназа 1 (ALDH1) є одним з найчастіше використовуваних маркерів ракових стовбурових клітин, проте питання щодо його значущості відносно окремих етапів колоректального канцерогенезу лишається до кінця не вивченим. Метою цього дослідження стало порівняння рівнів імуногістохімічної експресії ALDH1 в поліпах і аденокарциномі дистальної товстої кишки. Проведено патоморфологічне та імуногістохімічне дослідження біопсійного матеріалу 40 пацієнтів (біоптати поліпів і гістологічно незміненої слизової оболонки дистальної товстої кишки), а також операційного матеріалу колоректальної аденокарциноми 30 пацієнтів. Установлено, що поліпи дистальної товстої кишки характеризуються цитоплазматичною експресією ALDH1 з медіаною відносної площі 25,63 (18,26; 30,42)% клітин стромы, а також, що експресія маркера епітеліоцитами виявляється виключно в диспластично змінених поліпах з медіаною площі 22,13 (17,22; 30,05)%. Колоректальна аденокарцинома

характеризується цитоплазматичною експресією ALDH1 з медіанами площі 40,22 (22,54; 47,77)% клітин стромы та 32,12 (23,64; 40,28)% ракових клітин. Показник площі ALDH1+ клітин варіює залежно від стадії карциноми за pTNM, при цьому медіана площі ALDH1+ клітин стромы достовірно збільшується при прогресії пухлини від I до III стадії, що відображає збільшення кількості клітин стромы, залучених до активації туморогенних сигнальних шляхів. Медіана площі ALDH1+ ракових клітин достовірно збільшується при прогресії пухлини від III до IV стадії, що відображає збільшення кількості ракових клітин, що набувають властивостей стовбурових, на просунутих стадіях колоректальної аденокарциноми. Порівняльний аналіз показників, отриманих для поліпів і карциноми, вказує на те, що медіана площі ALDH1+ клітин стромы поліпів в 2 рази менша за медіану площі ALDH1+ клітин стромы карциноми, а медіана площі ALDH1+ епітеліоцитів поліпів в 1,5 рази менша за медіану площі ALDH1+ ракових клітин.

During the last decade, a significant amount of data supporting the hypothesis of cancer stem cells (CSCs) has been accumulated. CSCs are cells that are present in cancer and have properties of normal stem cells including the ability to self-renewal and the ability to differentiate towards any type of cells that are present in the same tumor [5]. Among the most used CSC markers in colorectal adenocarcinoma (CRA) is aldehyde dehydrogenase 1 (ALDH1) [7].

ALDH1 is an oxidoreductase that provides oxidation of a wide range of endo- and exogenous aldehydes. The main function of ALDH1 is to protect cells under oxidative stress. Moreover, ALDH1 plays a key role in biosynthesis of some regulatory molecules, such as retinoic acid, γ -aminobutyric acid, and betaine [11].

ALDH1 is well known as a “metabolic marker” of stem cells, that is based on the main function of the enzyme – protection of cells from oxidative damage and, as a consequence, providing their high survival rate [4]. ALDH1 is expressed by normal stem cells, progenitor cells, and CSCs [11]. A compelling amount of data regarding the significance of ALDH1 expression in various types of cancer has been accumulated in the current literature [3, 4, 10]. A lot of research were devoted to studying of ALDH1 expression significance in CRA, however, the data obtained are contradictory. In some studies, it was shown that ALDH1 is an independent prognostic marker, high expression of which directly correlates with worsening of prognosis, as well as with clinical and pathomorphological characteristics of the tumor [9]. At the same time, it was shown that the expression of ALDH1 does not correlate with the CRA stage [2]. Furthermore, in the modern literature, there are only single data regarding the features of ALDH1 expression in colorectal polyps, which do not provide a comprehensive picture of the marker significance in the context of colorectal cancerogenesis [9].

The aim of the study was to compare ALDH1 immunohistochemical expression levels in polyps and adenocarcinoma of the distal colon.

MATERIALS AND METHODS OF RESEARCH

Histopathological and immunohistochemical (IHC) studies of biopsies from 40 patients (biopsies of po-

lyps and histologically non-changed mucosa of the distal colon), as well as surgical material of colorectal adenocarcinoma from 30 patients, were carried out.

The biopsies and the surgical material were fixed in 10 % neutral buffered formalin and were paraffin-embedded. The features of the studied samples histological structure were studied in sections stained by hematoxylin and eosin, and in sections stained by PAS-reaction as well.

IHC study was conducted according to the protocol provided by the manufacturer of used antibodies. Monoclonal antibodies against ALDH1 (ALDH1A1, Clone 5A11, Thermo Scientific, USA), as well as visualization system EnVision FLEX with diaminobenzidine (DAKO, USA), were used. The results of IHC reactions were studied using Axioplan-2 microscope (Carl Zeiss, Germany). In each case, the area of ALDH1-positive cells was estimated in 5 standardized microscope fields of view at $\times 200$ magnification. The area was estimated by the method of photo digital morphometry: calculation of immunopositive pixels number in a digital image with further comparing to total pixels number in the image was carried out. As a result, the number of immunopositive pixels was expressed in % [1].

The obtained data were statistically processed using the STATISTICA® for Windows 13.0 package (StatSoft Inc., license no. JPZ804I382130ARCN10-J). The median (Me), the lower and upper quartiles (Q1; Q3) were calculated. Comparison between two study groups was carried out using the Mann-Whitney test. The results were considered statistically significant at the 95% level ($p < 0.05$) [8].

RESULTS AND DISCUSSION

It was found that distal colonic polyps are characterized by cytoplasmic ALDH1 expression in stromal cells, with the median of relative area of ALDH1+ cells equal to 25.63 (18.26; 30.42)% stromal cells (fig. 1). ALDH1+ epitheliocytes are revealed exclusively in dysplastic polyps with the median of the area that is equal to 22.13 (17.22; 30.05)% epitheliocytes.

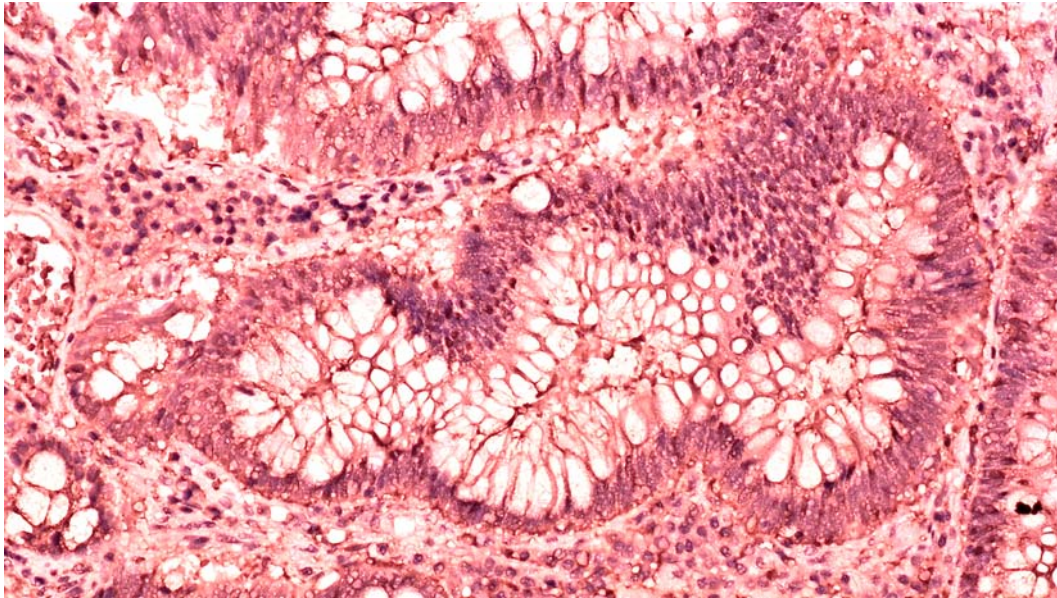


Fig. 1. ALDH1 expression in distal colonic polyp. ALDH1A1/Clone 5A11 (Thermo Scientific, USA) ×200

Colorectal adenocarcinoma is characterized by cytoplasmic ALDH1 expression in both stromal and cancer cells. The median of relative area of ALDH1+ stromal cells is equal to 40.22 (22.54;

47.77)%, while the median of relative area of ALDH1+ cancer cells is equal to 32.12 (23.64; 40.28)% (fig. 2).

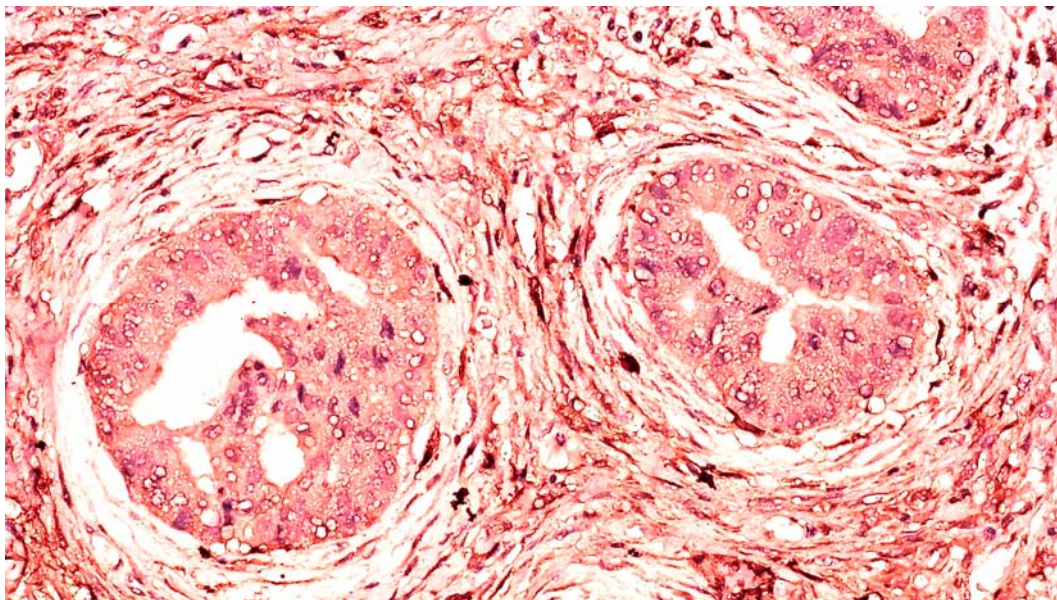


Fig. 2. ALDH1 expression in colorectal adenocarcinoma. ALDH1A1/Clone 5A11 (Thermo Scientific, USA) ×200

Based on the results of histopathological examination, the CRA study group was divided into subgroups according to the pTNM stages. Comparative analysis for the data obtained for the sequent stages was carried out. The median of relative area of ALDH1+ stromal cells in CRA I stage is equal to 20.66 (18.51; 21.47)% vs. the median of

relative area of ALDH1+ stromal cells in CRA II stage is equal to 25.75 (20.56; 32.86)%, $p < 0.05$; the median of relative area of ALDH1+ stromal cells in CRA II stage vs. the median of relative area of ALDH1+ stromal cells in CRA III stage is equal to 44.93 (41.17; 50.01)%, $p < 0.05$; the median of relative area of ALDH1+ stromal cells in CRA III stage

vs. the median of relative area of ALDH1+ stromal cells in CRA IV stage is equal to 48.36 (42.15; 55.17)%, $p > 0.05$.

The median of relative area of ALDH1+ cancer cells in CRA I stage is equal to 26.04 (21.65; 31.94)% vs. the median of relative area of ALDH1+ cancer cells in CRA II stage is equal to 30.31 (21.17; 35.68)%, $p > 0.05$; the median of relative area of ALDH1+ cancer cells in CRA II stage vs. the median of relative area of ALDH1+ cancer cells in CRA III stage is equal to 30.28 (21.19; 35.47)%, $p > 0.05$; the median of relative area of ALDH1+ cancer cells in CRA III stage vs. the median of relative area of ALDH1+ cancer cells in CRA IV stage is equal to 48.71 (38.72; 51.16)%, $p < 0.05$.

Thereby, statistically significant increase of the area of ALDH1+ stromal cells in CRA during its progression from I to III stages was revealed. Statistically significant increase of the area of ALDH1+ cancer cells in CRA during its progression from III to IV stages was revealed as well. According to the literature, ALDH1+ cells of CRA stroma are involved in activation of several signaling pathways, including MEK/ERK- and Wnt/ β -catenin cascades. It is well known that activation of those cascades forms the basis of invasiveness in different carcinomas, including CRA [3]. ALDH1+ cancer cells are known as cancer cells undergoing epithelial-mesenchymal transition. Based on the literature, the expression of ALDH1 by cancer cells is associated with loss of E-cadherin expression and appearance of vimentin expression [6]. In addition, ALDH1 expression by cancer cells displays their acquisition of stemness. The enzyme performs its main detoxifying function in these cells that leads to their high survival rate [11].

Comparative analysis for the data obtained for both distal colonic polyps and colorectal adenocarcinoma was performed as well. It was revealed that the median of area of ALDH1+ stromal cells in polyps is 2 times smaller than that in CRA: 25.63 (18.26; 30.42)% vs. 40.22 (22.54; 47.77)%, $p < 0.05$. The median of area of ALDH1+ epitheliocytes in polyps is 1.5 times smaller than that for cancer cells in CRA: 22.13 (17.22; 30.05)% vs. 32.12 (23.64; 40.28)%, $p < 0.05$.

It has already been said that in the modern literature there are only single data regarding the features of ALDH1 expression in colorectal polyps [9]. In this study it was shown that the medians of ALDH1+ cells areas are significantly higher in CRA, when compared with those in polyps, that indicates an increasing role of ALDH1 in progression of advanced stages of colorectal carcinogenesis.

CONCLUSIONS

1. Distal colonic polyps are characterized by cytoplasmic expression of ALDH1, the median of ALDH1+ stromal cells area in polyps is 2 times smaller than the median of ALDH1+ stromal cells area in carcinoma, and the median of ALDH1+ epitheliocytes area in polyps is 1.5 times smaller than the median of ALDH1+ cancer cells area.

2. Colorectal adenocarcinoma is characterized by cytoplasmic expression of ALDH1, the median of ALDH1+ stromal cells area significantly increases during the tumor progression from stage I to stage III.

3. The median of ALDH1+ cancer cells area significantly increases during the tumor progression from stage III to stage IV that displays increasing in number of cancer cells that acquire stemness on advanced stages of colorectal adenocarcinoma.

Conflict of interests. The authors declare no conflict of interest.

REFERENCES

1. Tumanskyi VO, Yevsieiev AV, Kovalenko IS, Zubko MD. [Patent of Ukraine 99314, IPC 2015.01 G01N 21/00 G06K 9/00 The technique of digital morphometry of immunohistochemical slides]. Biuletен, 10. Ukrainian.
2. Vermani L, Kumar NS, Talukdar A, Deka M, Kannan R, Kumar R. Abstract 4924: High ALDH1 expression in colorectal carcinoma could predict early onset of the disease. *Cancer Research*. 2019;79(13):4924. doi: <https://doi.org/10.1158/1538-7445.AM2019-4924>
3. Singh S, Arcaroli J, Thompson DC, Messersmith W, Vasiliou V. Acetaldehyde and retinaldehyde-metabolizing enzymes in colon and pancreatic cancers. *Advances in experimental medicine and biology*. 2015;815:281-94. doi: https://doi.org/10.1007/978-3-319-09614-8_16
4. Kozovska Z, Patsalias A, Bajzik V, Durinikova E, Demkova L, Jargasova S, Smolkova B, Plava J, Kuce-rova L, Matuskova M. ALDH1A inhibition sensitizes colon cancer cells to chemotherapy. *BMC Cancer*. 2018;18(1):656. doi: <https://doi.org/10.1186/s12885-018-4572-6>
5. Moharil RB, Dive A, Khandekar S, Bodhade A. Cancer stem cells: An insight. *J Oral Maxillofac Pathol*. 2017;21(3):463. doi: https://doi.org/10.4103/jomfp.JOMFP_132_16
6. Choi JE, Bae JS, Kang MJ, Chung MJ, Jang KY, Park HS, Moon WS. Expression of epithelial-mesenchymal transition and cancer stem cell markers in colorectal adenocarcinoma: Clinicopathological significance. *Oncol Rep*. 2017;38(3):1695-705. doi: <https://doi.org/10.3892/or.2017.5790>
7. Kuşoğlu A, Biray Avcı Ç. Cancer stem cells: A brief review of the current status. *Gene*. 2019;681:80-85. doi: <https://doi.org/10.1016/j.gene.2018.09.052>

8. Petrie A, Sabin C. Medical Statistics at a Glance. 4th edition. Wiley-Blackwell; 2019. p. 208.

9. Chen J, Xia Q, Jiang B, Chang W, Yuan W, Ma Z, Liu Z, Shu X. Prognostic Value of Cancer Stem Cell Marker ALDH1 Expression in Colorectal Cancer: A Systematic Review and Meta-Analysis. *PLoS One*. 2015;10(12):e0145164.

doi: <https://doi.org/10.1371/journal.pone.0145164>

10. Ruscito I, Darb-Esfahani S, Kulbe H, Bellati F, Zizzari IG, Koshkaki HR, Napoletano C, Caserta D,

Rughetti A, Kessler M, Sehouli J, Nuti M, Braicu EI. The prognostic impact of cancer stem-like cell biomarker aldehyde dehydrogenase-1 (ALDH1) in ovarian cancer: A meta-analysis. *Gynecol Oncol*. 2018;150(1):151-7. doi: <https://doi.org/10.1016/j.ygyno.2018.05.006>

11. Vassalli G. Aldehyde Dehydrogenases: Not Just Markers, but Functional Regulators of Stem Cells. *Stem cells international*. 2019;2019:3904645.

doi: <https://doi.org/10.1155/2019/3904645>

СПИСОК ЛІТЕРАТУРИ

1. Спосіб фотоцифрової морфометрії імуногістохімічних препаратів: пат 99314 Україна. МПК 2015.01 G01N 21/00 G06K 9/00; заявник і патентовласник Запорізький держ. мед. ун-т.; заявл. 29.12.14.; опубл. 25.05.15, Бюл. № 10.

2. Abstract 4924: High ALDH1 expression in colorectal carcinoma could predict early onset of the disease / L. Vermani et al. *Cancer Research*. 2019. Vol. 79. Iss. 13. P. 4924. DOI: <https://doi.org/10.1158/1538-7445.AM2019-4924>

3. Acetaldehyde and retinaldehyde-metabolizing enzymes in colon and pancreatic cancers / S. Singh et al. *Advances in experimental medicine and biology*. 2015. Vol. 815. P. 281-294. DOI: https://doi.org/10.1007/978-3-319-09614-8_16

4. ALDH1A inhibition sensitizes colon cancer cells to chemotherapy / Z. Kozovska et al. *BMC Cancer*. 2018. Vol. 18, No. 1. P. 656. DOI: <https://doi.org/10.1186/s12885-018-4572-6>.

5. Cancer stem cells: An insight / R.B. Moharil et al. *J Oral Maxillofac Pathol*. 2017. Vol. 21. No. 3. P. 463. DOI: https://doi.org/10.4103/jomfp.JOMFP_132_16

6. Expression of epithelial-mesenchymal transition and cancer stem cell markers in colorectal adeno-

carcinoma: Clinicopathological significance / J. E. Choi et al. *Oncol Rep*. 2017. Vol. 38. No. 3. P. 1695-1705. DOI: <https://doi.org/10.3892/or.2017.5790>

7. Kuşoğlu A., Biray Avcı Ç. Cancer stem cells: A brief review of the current status. *Gene*. 2019. Vol.681. P. 80-85. DOI: <https://doi.org/10.1016/j.gene.2018.09.052>

8. Petrie A., Sabin C. Medical Statistics at a Glance. 4th ed. Wiley-Blackwell. 2019. 208 p.

9. Prognostic Value of Cancer Stem Cell Marker ALDH1 Expression in Colorectal Cancer: A Systematic Review and Meta-Analysis / J. Chen et al. *PLoS One*. 2015. Vol. 10. Iss. 12. e0145164. DOI: <https://doi.org/10.1371/journal.pone.0145164>

10. The prognostic impact of cancer stem-like cell biomarker aldehyde dehydrogenase-1 (ALDH1) in ovarian cancer: A meta-analysis / I. Ruscito et al. *Gynecol Oncol*. 2018. Vol. 150, No. 1. P. 151-157. DOI: <https://doi.org/10.1016/j.ygyno.2018.05.006>

11. Vassalli G. Aldehyde Dehydrogenases: Not Just Markers, but Functional Regulators of Stem Cells. *Stem cells international*. 2019. Vol. 2019. P. 3904645. DOI: <https://doi.org/10.1155/2019/3904645>

Стаття надійшла до редакції
10.09.2020

