

UDC 617.53/.53-002.3-089.816

<https://doi.org/10.26641/2307-0404.2020.1.200397>

V.A. Malanchuk ¹,
A.V. Sidoryako ²,
S.V. Sidoryako ²

VACUUM DRAINAGE OF TISSUES IN TREATMENT OF INFLAMMATORY DISEASES OF THE MAXILLO-FACIAL AREA AND NECK

Bogomolets National Medical University¹

Department of Surgical Dentistry and Maxillofacial Surgery

Zoologichna str., 1, Kyiv, 03057, Ukraine

SE «Zaporizhzhya Medical Academy of Postgraduate Education of the Ministry of Health of Ukraine»²

Winter bl, 20, Zaporizhzhia, 69096, Ukraine

Національний медичний університет ім. О.О. Богомольця¹

кафедра хірургічної стоматології та щелепно-лицьової хірургії

вул. Зоологічна, 1, Київ, 03057, Україна

ДЗ «Запорізька медична академія післядипломної освіти МОЗ України»²

бул. Винтера, 20, Запоріжжя, 69096, Україна

e-mail: andrey.sidoryako19@gmail.com

Цитування: Медичні перспективи. 2020. Т. 25, № 1. С. 45-51

Cited: Medicni perspektivi. 2020;25(1):45-51

Key words: vacuum drainage, phlegmons of the maxillofacial area and neck, maxillofacial surgery

Ключові слова: вакуумний дренаж, флегмони щелепно-лицьової ділянки та шиї, щелепно-лицьова хірургія

Ключевые слова: вакуумный дренаж, флегмоны челюстно-лицевой области и шеи, челюстно-лицевая хирургия

Abstract. Vacuum drainage of tissues in treatment of inflammatory diseases of the maxillo-facial area and neck.

Malanchuk V.A., Sidoryako A.V., Sidoryako S.V. Objective of the study: to increase the efficiency of drainage of tissues with phlegmons of the maxillo-facial area and neck using vacuum drainage. The device was used in 55 people with phlegmons of the maxillo-facial area and neck, aged from 21 to 65 years in the maxillo-facial department of the City Clinical Hospital for Emergency and Medical Care, Zaporizhzhya. The proposed device improves the efficiency of evacuation of exudate from the wound. The decrease in the number of complications, the occurrence of bedsores in the wound caused by tubular drainage is observed, it prevents the spread of the inflammatory process in the adjacent tissue spaces. The improvement of the clinical picture and stabilization of the general condition in 53 (96.4%) patients of the second group was noted on the 2.4±0.7 day after surgery, in 43 (95.6%) patients of the first group – on 3.7±0.6 day; the intensity of the pain syndrome decreased on average on 3.2±0.4 day. In 48 (87.3%) patients of the second group suppuration was absent already on 2.4±0.6 day, the formation of granulations – on 3.2±0.5 day, and complete cleansing and convergence of the wound edges – on 6.2±0.7 day. In 4 patients of the first and second groups, the healing time of the postoperative wound was longer: the cessation of suppuration was noticed on 6th-7th day, the appearance of granulations – on 7th-8th day, complete cleansing, and the marginal convergence of the wound – on 11.2±0.8th day $p<0,001$. Vacuum drainage accelerates the onset of the second phase of the inflammatory process, reduces the dynamics of the disease course and the patient's recovery at least twice.

Реферат. Вакуумное дренирование тканей при лечении воспалительных заболеваний челюстно-лицевой области и шеи. Маланчук В.А., Сидоряко А.В., Сидоряко С.В. Цель исследования: повысить эффективность дренирования тканей при флегмонах челюстно-лицевой области и шеи с помощью вакуумного дренажа.

Устройство использовали у 55 человек в челюстно-лицевом отделении ГКБЭ и СМП г. Запорожся с флегмонами челюстно-лицевой области и шеи в возрасте от 21 до 65 лет. Предложенное устройство обеспечивает повышение эффективности эвакуации экссудата из раны. Наблюдается уменьшение количества осложнений, возникновения пролежней в ране от трубчатого дренажа и предотвращает распространение воспалительного процесса в соседние тканевые пространства. Улучшение клинической картины и стабилизация общего состояния у 53 (96,4%) больных второй группы было на 2,4±0,7 сутки после операции, у 43 (95,6%) пациентов первой группы – на 3,7±0,6 сутки, уменьшилась интенсивность болевого синдрома в среднем на 3,2±0,4 сутки. У 48 (87,3%) пациентов второй группы гноетечение отсутствовало уже на 2,4±0,6 сутки, образование грануляций – на 3,2±0,5 сутки, а полное очищение и сближение краев раны – на 6,2±0,7 сутки. У 4 пациентов первой и второй групп сроки заживления послеоперационной раны были более продолжительными: прекращение гноетечения у них было отмечено к 6-7 суткам, появление грануляций – к 7-8 суткам, полное очищение и краевое сближение раны – к 11,2±0,8 суткам при ($p<0,001$). Авторский дренаж способствует ускорению наступления второй фазы воспалительного процесса, сокращению динамики течения заболевания и выздоровлению больного как минимум в два раза.

The problem of adequate drainage of the wound, after opening of the inflammatory infiltrate is particularly relevant in the treatment of patients with phlegmons in the deep spaces of the maxillofacial area: the pharyngeal, pterygo-maxillary, subtemporal, parotid-masticatory areas and neck, including the tissue of the cervical neurovascular bundle [1, 3, 4, 8].

However, in the treatment of purulent wounds, classical aspiration is often ineffective due to the suction-obstructive effect. In connection with the mentioned above, it is necessary to improve the methods and devices for vacuum aspiration in maxillofacial surgery [2, 5, 6, 7].

In recent years, a large number of methods have been proposed for treating these pathological conditions using various devices, antiseptic drugs, ointment compositions, hyperbaric oxygenation, low-frequency ultrasound and laser irradiation. Despite the progress made, complications that threaten the lives of patients are increasingly common: sepsis, meningitis, cavernous sinus thrombosis, mediastinitis. In this regard, the development of new methods and devices for the treatment of acute purulent-inflammatory processes in the maxillofacial area by changing their design or the material from which they are made is one of the urgent tasks of maxillofacial surgery.

The purpose of the study: to increase the efficiency of drainage of tissues with phlegmons of the maxillofacial area and neck using vacuum drainage.

MATERIALS AND METHODS OF RESEARCH

All procedures, conducted in the study with the participation of patients, complied with the ethical standards of the institutional and national research committee, as well as the 1975 Helsinki Declaration and its 1983 revision.

Recently, more and more active using of drainage aspiration devices with an optimal shape and properties takes place. At the same time, the physical factor of the treatment of a postoperative wound is used, that is vacuum. For the treatment of patients with phlegmons of the maxillofacial area and neck at the stage of exudation, active drainage of purulent cavities was applied. The "Method of drainage of purulent wounds of the maxillofacial area and the device for its drainage" was used, application No. 2018 02696 from 16.03.18.

It was carried out the diagnostics and complex treatment of 60 patients with odontogenic phlegmons who were hospitalized in the department of maxillofacial surgery on the basis of the Department of Surgical and Therapeutic Dentistry of the State Establishment "Zaporizhzhya Medical Academy of Postgraduate Education of the Ministry of Health of

Ukraine". Patients were divided into 2 groups: 1 gr. – 45 patients were treated with the traditional method. 2 gr. – 55 patients, the treatment of which was performed in a traditional way and vacuum drainage of purulent wounds at the stage of exudation was applied as well.

Upon admission to the hospital, all patients were given a complex examination. Surgery was performed according to the standard technique under the local anesthesia, and under general anesthesia, depending on the prevalence of the inflammatory process. It consisted from a wide dissection and drainage of a purulent focus. As a rule, during the opening of the phlegmon, the "causative" tooth, which was the source of infection was removed. Cytological monitoring of the wound condition was performed as a criterion of the effectiveness of the therapy: for the first time – after opening and drainage of the suppurative focus, on the third, on the fifth and seventh days of the treatment.

The use of vacuum drainage increased the efficiency of wound exudate evacuation and led to a decrease in the number of complications due to the likelihood of the spread of the inflammatory process in neighboring cell spaces.

To ensure the physiological nature of wound healing, the form of the drainage device copied the form of a purulent cavity. It was made individually according to the shape of the patient's purulent cavity, which reduced the probability of bedsores in the wound. Installing the drainage, the limiter immersion was covered with a grease based on the ointment that serves as a sealing part of this device.

The device was made of medical plastics with through porosity and a discharge pipe, the size of the frame is less than the volume of the cavity of a purulent wound by 10-30%, the dimensions of the holes of the wall of the frame are 0.1-0.5 mm, and they are located on the surface of the device in contact with tissues (Fig. 1). Additionally, the device has an immersion limiter in the wound, where the discharge pipe is located.

The diameter of the holes on the surface is 0.1-0.5 mm. The number of holes, per 1 cm² of the area of their location, is chosen because, according to the anatomical structure, the capillaries in the striated muscles have a clearance of 5-6 microns, and, the nature of the porosity of the vacuum device for drainage depends on it (Fig. 2). The optimal size of the holes should be in the range of 0.1-0.5 mm., they will expel well the exudate with a diameter of this kind and the germination of capillaries into the lumens of the holes will not occur.

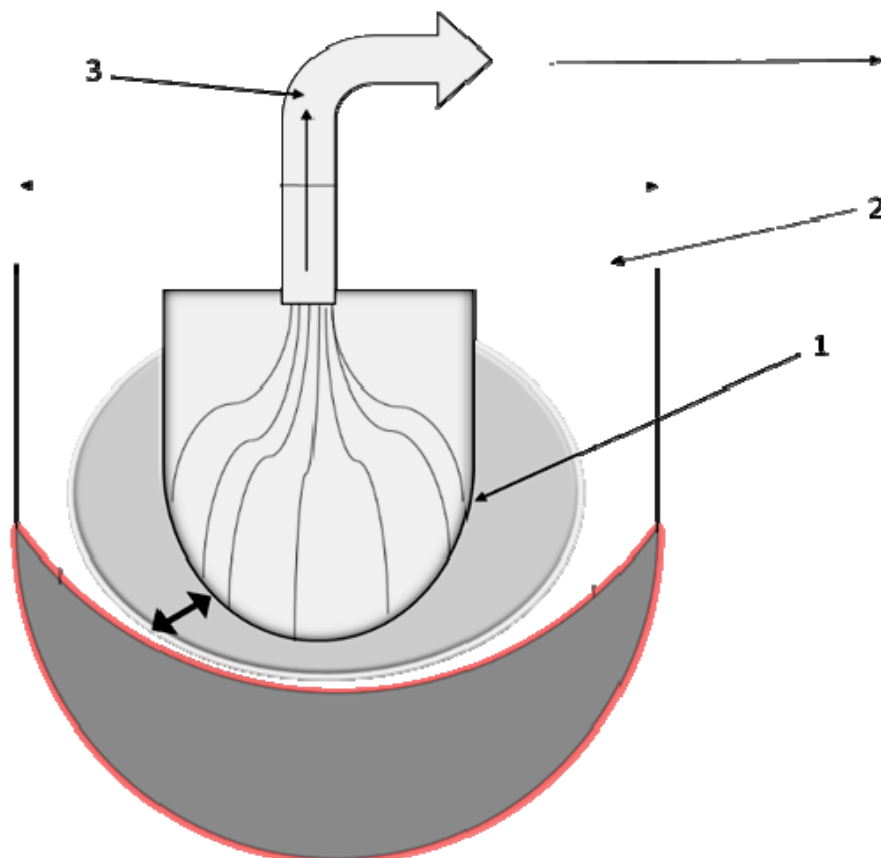


Fig. 1. The device is shown on the illustration: 1. The device made of medical plastics to preserve the volume of the cavity. 2. Discharge pipe for exudate outflow. 3. Immersion limiter in the interstitial cavity

It is very important fact that it is not technically possible to make a hole in the device less than 0.5 mm.

Blood pressure in the pre-capillaries also plays an important role in the choice of the negative pressure value in the device, since it should not be more than in the capillaries of the wound. The better the conditions of exudation in the wound, and therefore, the more the blood pressure drops in the arterial segment of the capillary bed.

Average blood pressure in capillaries differs with relative stability; on arterial sections of capillaries of the pulmonary circulation it is 30-50 mm Hg, and on venous sections, due to energy consumption for overcoming resistance along the length of the capillary and filtration, it decreases to 25-15 mm Hg

A significant effect on capillary blood pressure and its dynamics during the capillary has a venous pressure. Therefore, the amount of negative pressure in the wound was maintained within 15-12 mm Hg. It was carried out under the control of an artificial pressure-generating apparatus.

The obtained laboratory research data were carried out in the International System of Units and processed by methods of variation statistics using the MedStat package and the statistical package EZR v.1.35 (Saitama Medical Center, Jichi Medical University, Saitama,

Japan, 2017), which is a graphical interface to RFSC (The R Foundation for Statistical Computing, Vienna, Austria)



Fig. 2. Individual Drainage



Fig. 3. Negative pressure device

RESULTS AND DISCUSSION

Observations showed a positive dynamics of the clinical course of phlegmon in the treatment of patients of the second group with vacuum drainage of wounds in addition to the main treatment method. The length of hospital stay was reduced, compared with patients in the first group. A cytological examination of smear samples was conducted on the third, fifth, seventh days in 2 groups of traditional treatment and after conducting an active vacuum drainage of wounds.

The improvement of the clinical picture and stabilization of the general condition in 53 (96.4%) patients of the second group was noted on the 2.4±0.7 day after surgery, in 43 (95.6%) patients of

the first group – on 3.7±0.6 day; the intensity of the pain syndrome decreased on average by on 3.2±0.4 day. In 48 (87.3%) patients of the second group of suppuration was absent already on 2.4±0.6 day, the formation of granulations – on 3.2±0.5 day, and complete cleansing and convergence of the wound edges – on 6.2±0.7 day. In 4 patients of the first and second groups, the healing time of the postoperative wound was longer: the cessation of suppuration was noticed on 6-7th day, the appearance of granulations – on 7-8th day, complete cleansing, and the marginal convergence of the wound – by 11.2±0.8 day p<0.001 (table).

Comparative characteristics of clinical indicators in patients with phlegmons of the maxillofacial area and neck M±SD

Indicator	First group (n=45) normal drainage	Second group (n=55) vacuum drainage
Objective general condition improvement, (day)	3.7±0.6	2.4±0.7
Reduction of pain syndrome, subjectively, (day)	3.2±0.4	2.5±0.8
Reduction of purulent discharge, (day)	4.2±0.7	2.4±0.6*
The appearance of granulations, (day)	4.5±0.9	3.2±0.5*
Complete wound cleansing, (day)	11.2±0.8	6.2±0.7*

Note: * - the difference is statistically significant compared with group I, p <0.001 for the Mann-Whitney criterion.

Superacryl medical drainage device proposed by us does not irritate the soft tissues of the wound cavity, is harmless to the body, has sufficient strength, does not deform and does not change its volume; at the moment of changing body temperature it maintains a smooth surface; has low thermal conductivity to maintain a constant temperature, of soft tissues containing the frame, it is easily disinfected; has a small proportion. Each time using this device, it is modeled individually, which ensures the accordance with the walls of the cavity and prevents a smaller percentage of the occurrence of bedsores. Through the use of immersion limiter in the cavity, the constancy of negative pressure and hermetic marginal adhesion to the wound is ensured.

The criterion for removing the device from the tissues was taken into account according to objective and subjective data: the state of health began to improve the next day after opening the phlegmons in both groups, eating food in the second group became much easier on 2nd day after surgery, the pain syndrome subsided after surgery in case of the absence of the spread of the inflammatory process in the adjacent anatomical spaces.

Wound clearance began on 2nd-3rd day 8 it was, covered with fibrin, at the bottom of the wound by the third day, the first granulation tissue appeared, in both groups. In the second group, it occupied the entire bottom of the wound. The calculation of the volume (V) of the purulent cavity from the imprint was carried out using the formula $V=\pi r^2 h$. After the calculations, the average volume of the purulent

cavity was approximately 10.5 cm^3 . After 3 days, measurements were done one more time. $V=7.2 \text{ cm}^3$ and this shows that approximately the volume of the purulent cavity decreases by 30 % in the second group, and on the fourth day the evacuation of traces of serious exudates was not observed, and the device was removed.

Epithelization of the edges of the wound surface was gradual. Already on the 2nd day after the start of treatment, it was noticed that the patient's body temperature dropped to 37.0° C , general blood test revealed a gradual decrease in the number of white blood cells to an average of $10-12 \cdot 10^9$, ESR did not decrease so quickly and remained above normal indices before discharge the patient from the hospital and ranged from 20-27 mm/h.

Cytological examination of the wound during treatment of phlegmon on the third day revealed a large migration of leukocytes (from 40 to 120 in the vision field), neutrophils were present and there was also a small number of epithelial cells.

The degree of infiltration was decreasing gradually, every day. Its dimensions around the periphery of the wound varied. The method of assessing the dynamics of the inflammatory process in patients with phlegmons of the maxillofacial area (patent No. 135040 Ukraine) was used, it provides a simplified control while maintaining the reliability of the results.

As can be seen from the graph, the decrease in the volume and amount of infiltrate at the periphery of the wound in the second group was significantly less compared with the first group of patients (Fig. 4).

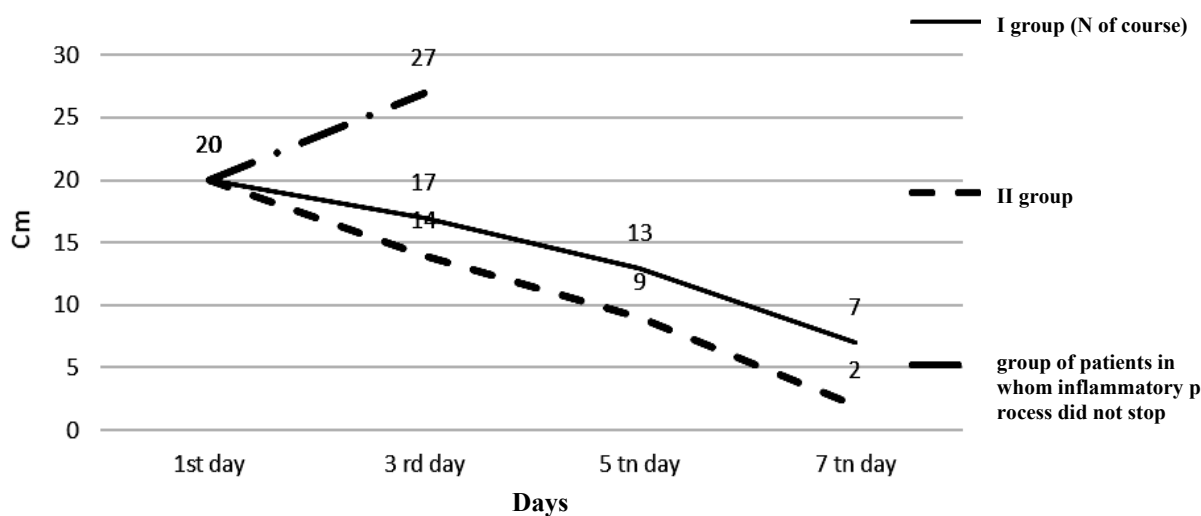


Fig. 4. Dynamics of changes in the size of inflammatory infiltrates of two groups of patients

There were also patients in whom the inflammatory process did not stop in the primary limits, with 4 patients from two groups. On the graph the deviation towards the increase in the resulting curve from the normal course is reflected, on average by 5-8 cm.

It was diagnosed the development of complications and the tactics of treatment was corrected as well, namely, it was changed the approach to antibiotic therapy and carried out the additional surgical interventions regarding the opening of new spaces and revision of already open cavities according to the classical method.

Using the proposed device there were no from its contours.

CONCLUSIONS

1. Vacuum drainage of purulent wounds by means of the device improves the efficiency of evacuation of the exudate from the wound and does not require bandaging two or three times a day,

preventing the active phase (exudation) of the inflammatory process.

2. During vacuum drainage, there is a decrease in the number of complications, the occurrence of bedsores in the wound and prevents the spread of the inflammatory process in the adjacent intercellular spaces.

3. Vacuum drainage accelerates the onset of the second phase of the inflammatory process, reducing the dynamics of the course of the disease and the patient's recovery at least twice.

Conflict of interests. The authors declare that they have no conflicts of interest that may be perceived as prejudicial to the impartiality of the article.

The article is a fragment of the RW: "Comprehensive treatment of patients with phlegmon of the maxillofacial region with an effect on the course of reparative processes", state registration number: 0117U000398.

REFERENCES

1. Malanchuk VA, Volovar AS, Garliauskite Vyu, et al. [Surgical dentistry and maxillofacial surgery: a textbook]. Kyiv: Logos; 2011. Russian.
2. Malanchuk VA, Sidoryako AV. [A method for evaluating the dynamics of the inflammatory process in patients with phlegmon of the maxillofacial area]. Ukraine patent 135040. IPC A61B 5/00, A61B 5/103. No. u2019 00530; 2019 Jan 18. Ukrainian.
3. Burnside V, Glasgow M, Ugurluoglu R. Vacuum-assisted closure in the treatment of craniofacial injuries. *J. Oral. Maxillofac. Surg.* 2010;68:935-42. doi: <https://doi.org/10.1016/j.joms.2009.09.113>
4. Benevides BS, Batista HMT, de Sousa Lopes MCM, et al. Descending Necrotizing Mediastinitis due to Odontogenic Infection: An unusual Case Report. [Internet]. *MOJ Surg.* 2017;4(6):00094. doi: <https://doi.org/10.15406/mojs.2017.04.00094>.
5. Yoshimoto A, Inoue T, Fujisaki M, et al. Efficacy of vacuum-assisted closure therapy on rehabilitation during the treatment for surgical site infection after cardiovascular surgery. *General Thoracic and Cardiovascular Surgery.* 2016 Aug;64(8):464-9. doi: <https://doi.org/10.1007/s11748-016-0664-x>
6. Asher SA, White HN, Golden JB, et al. Negative pressure wound therapy in head and neck surgery. *JAMA Facial Plast. Surg.* 2014;16(2):120-6. DOI: <https://doi.org/10.1001/jamafacial.2013.2163>
7. Flaviana Soares, Jonas Dantas Batista. [Rocha Considerations for the spread of odontogenic infections – diagnosis and treatment]. *Oral and Maxillofacial Surgery.* 2015;2(16):341-358.
8. Ter-Asaturov GP. Some issues of the pathogenesis of odontogenic phlegmon. *Dentistry.* 2015;1:20-27.

СПИСОК ЛІТЕРАТУРИ

1. Маланчук В. А. Хирургическая стоматология и челюстно-лицевая хирургия учебник: в 2 т. Т. 1. Киев: Логос, 2011.
2. Маланчук В. А., Сидоряко А. В. Способ оценки динамики воспалительного процесса у пациентов с флегмоной челюстно-лицевой области: пат. 135040 Украина: МПК А61В 5/00, А61В 5/103. № u2019 00530; заяв. 18.01.2019; опубл. 10.06.2019, Бюл. № 11.
3. Burnside V., Glasgow M., Ugurluoglu R. Vacuum-assisted closure in the treatment of craniofacial injuries. *J. Oral. Maxillofac. Surg.* 2010. Vol. 68. P. 935-942. DOI: <https://doi.org/10.1016/j.joms.2009.09.113>
4. Descending Necrotizing Mediastinitis due to Odontogenic Infection: An unusual Case Report / B. S. Benevides, et al. *MOJ Surg.* 2017. Vol. 4, No. 6. e00094. DOI: <https://doi.org/10.15406/mojs.2017.04.00094>. URL: <http://medcraveonline.com/MOJS/MOJS-04-00094>
5. Efficacy of vacuum-assisted closure therapy on rehabilitation during the treatment for surgical site infection after cardiovascular surgery / A. Yoshimoto, et al. *General Thoracic and Cardiovascular Surgery.* 2016. Aug. (Vol. 64, No. 8). P. 464-469. DOI: <https://doi.org/10.1007/s11748-016-0664-x>

6. Negative pressure wound therapy in head and neck surgery / S. A. Asher, et al. *JAMA Facial Plast. Surg.* 2014. Vol. 16, No. 2. P. 120-126. DOI: <https://doi.org/10.1001/jamafacial.2013.2163>

7. Flaviana Soares Rocha, Jonas Dantas Batista. Considerations for the spread of odontogenic infections –

diagnosis and treatment. *Oral and Maxillofacial Surgery.* 2015. Vol. 2, Ch. 16. P. 341-358.

8. Ter-Asaturov G. P. Some issues of the pathogenesis of odontogenic phlegmon. *Dentistry.* 2015 Vol. 1. P. 20-27.

Стаття надійшла до редакції
15.10.2019

